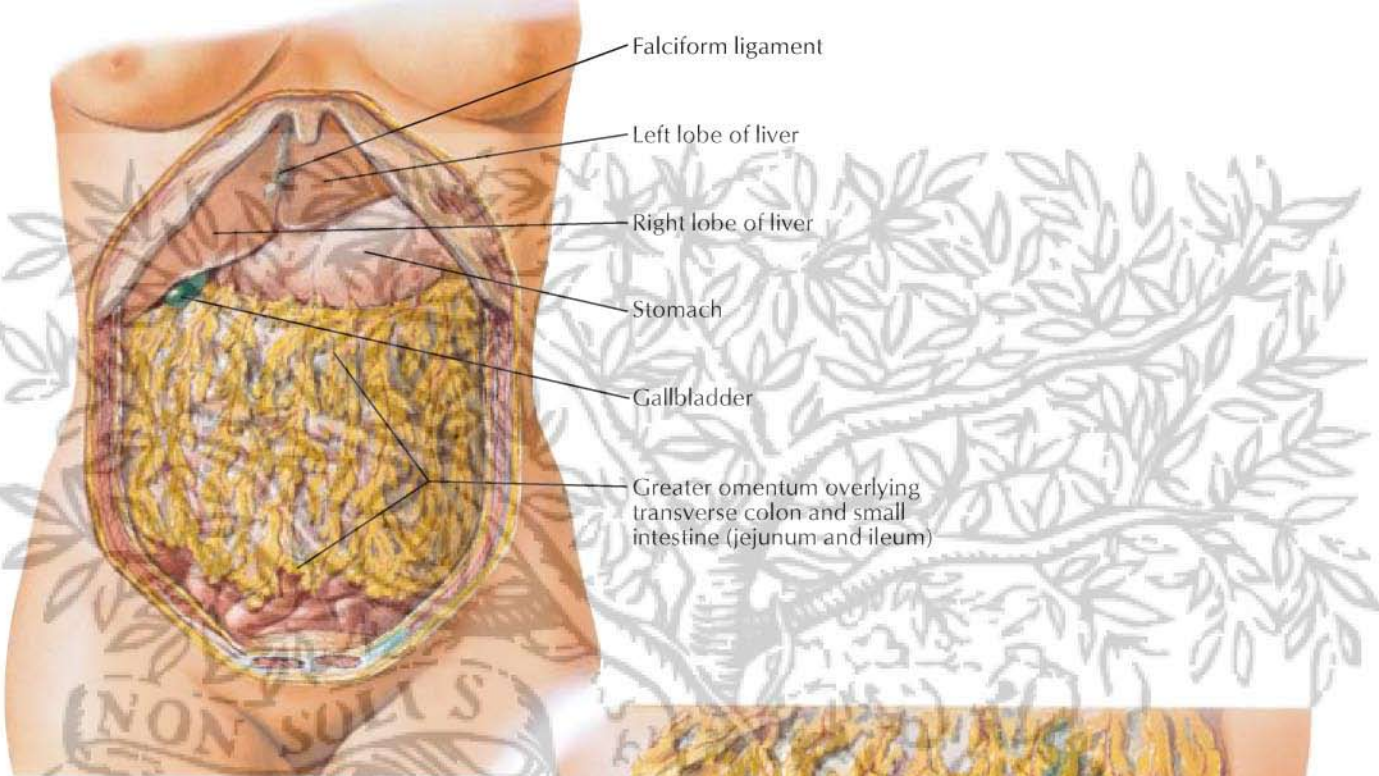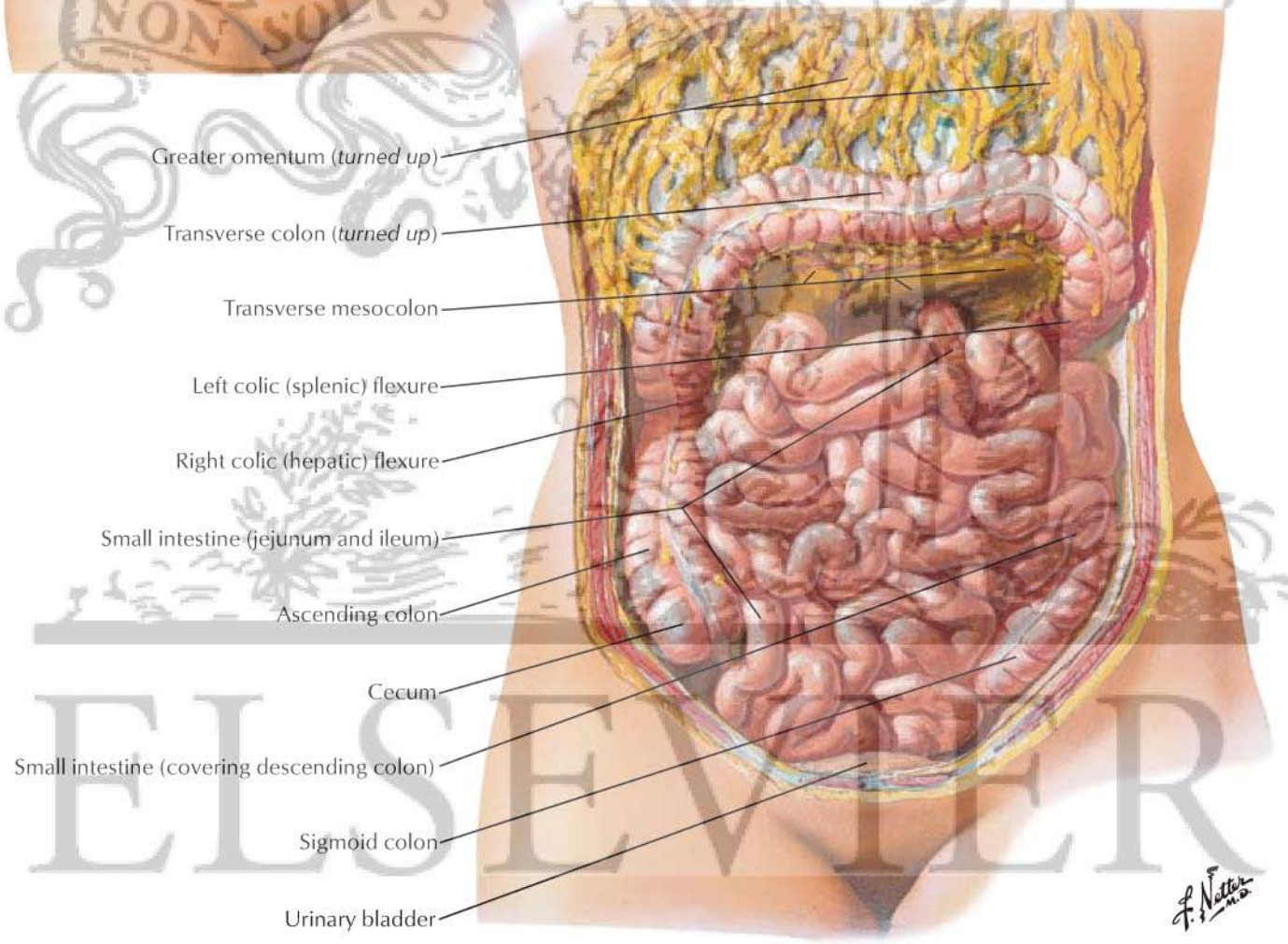


- Falciform ligament
- Left lobe of liver
- Right lobe of liver
- Stomach
- Gallbladder
- Greater omentum overlying transverse colon and small intestine (jejunum and ileum)



- Greater omentum (turned up)
- Transverse colon (turned up)
- Transverse mesocolon
- Left colic (splenic) flexure
- Right colic (hepatic) flexure
- Small intestine (jejunum and ileum)
- Ascending colon
- Cecum
- Small intestine (covering descending colon)
- Sigmoid colon
- Urinary bladder

ELSEVIER

F. Netter M.D.