

Anterior view

Note: Only muscles innervated by musculocutaneous nerve shown

Musculocutaneous nerve (C5, 6, 7)

Coracobrachialis muscle

Biceps brachii muscle (retracted)

Brachialis muscle

Articular branch

Lateral antebrachial cutaneous nerve

Anterior branch

Posterior branch

Medial Posterior Lateral } Cords of brachial plexus

Medial brachial cutaneous nerve

Medial antebrachial cutaneous nerve

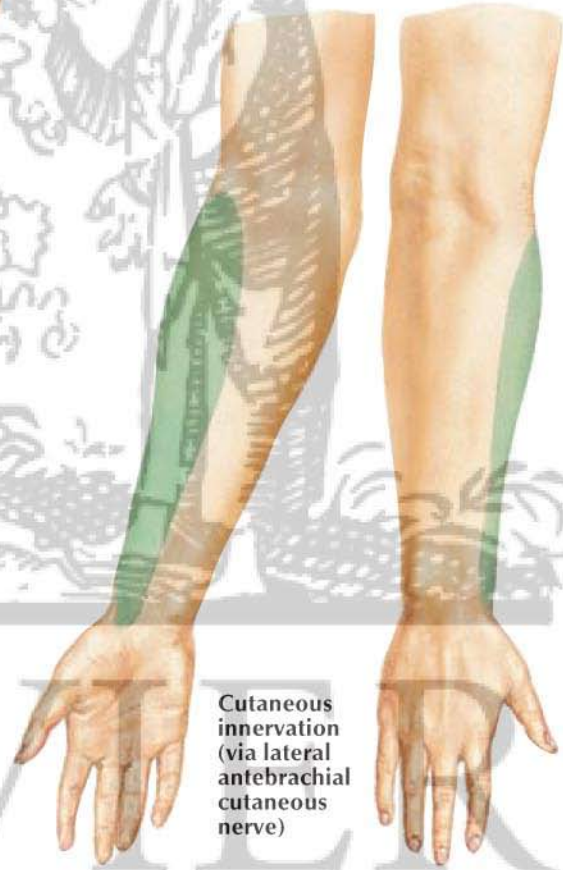
Ulnar nerve

Median nerve

Radial nerve

Axillary nerve

F. Netter M.D.



Cutaneous innervation (via lateral antebrachial cutaneous nerve)

Anterior (palmar) view

Posterior (dorsal) view