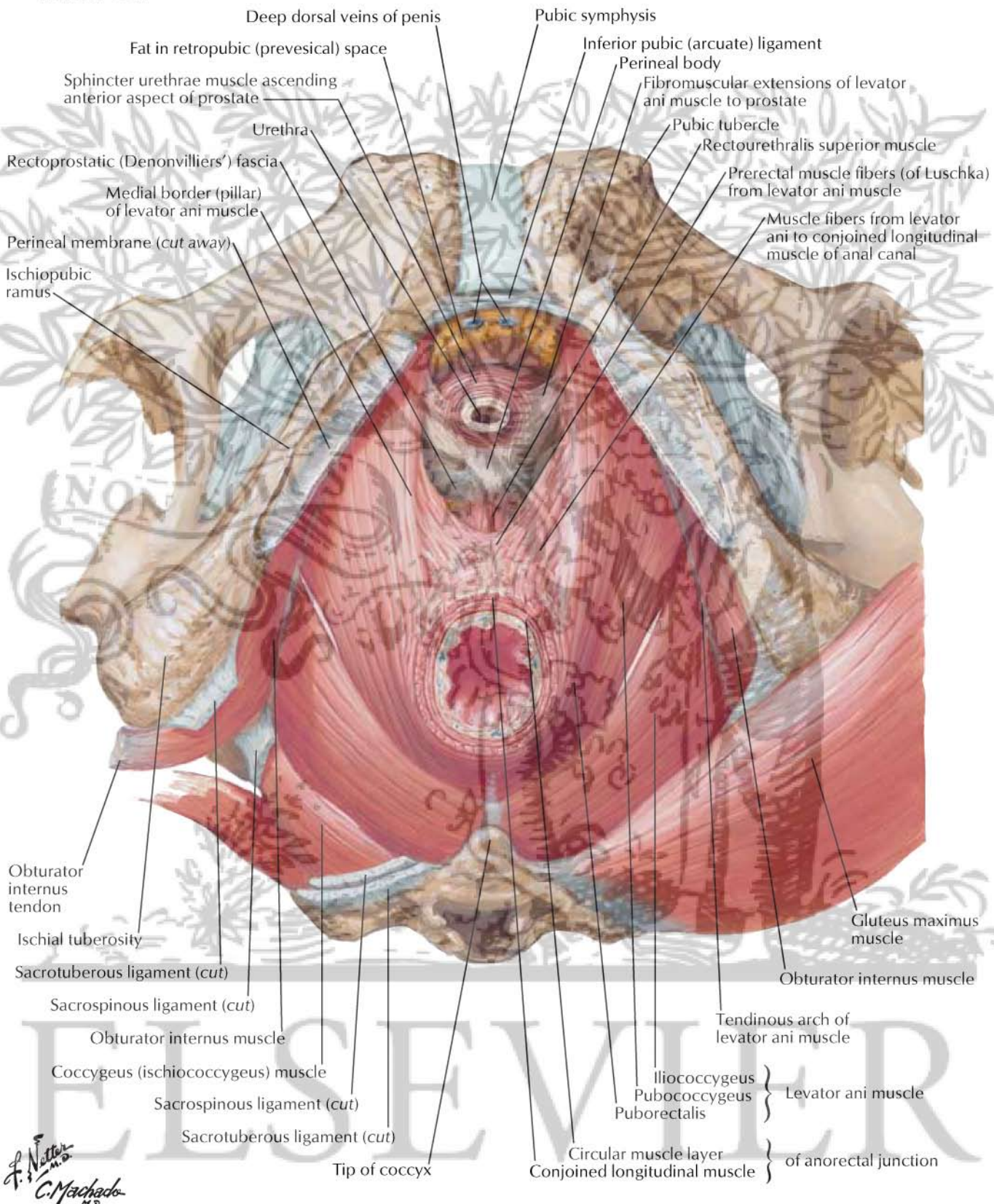


Inferior view



Deep dorsal veins of penis

Pubic symphysis

Fat in retropubic (prevesical) space

Inferior pubic (arcuate) ligament

Sphincter urethrae muscle ascending
anterior aspect of prostate

Perineal body

Fibromuscular extensions of levator
ani muscle to prostate

Urethra

Pubic tubercle

Rectourethralis superior muscle

Rectoprostatic (Denonvilliers') fascia

Prerectal muscle fibers (of Luschka)
from levator ani muscle

Medial border (pillar)
of levator ani muscle

Muscle fibers from levator
ani to conjoined longitudinal
muscle of anal canal

Perineal membrane (*cut away*)

Ischiopubic
ramus

Obturator
internus
tendon

Gluteus maximus
muscle

Ischial tuberosity

Obturator internus muscle

Sacrotuberous ligament (*cut*)

Sacrospinous ligament (*cut*)

Tendinous arch of
levator ani muscle

Obturator internus muscle

Coccygeus (ischiococcygeus) muscle

Iliococcygeus
Pubococcygeus
Puborectalis

Levator ani muscle

Sacrospinous ligament (*cut*)

Sacrotuberous ligament (*cut*)

Circular muscle layer
Conjoined longitudinal muscle }
of anorectal junction

Tip of coccyx

F. Netter M.D.
C. Machado M.D.