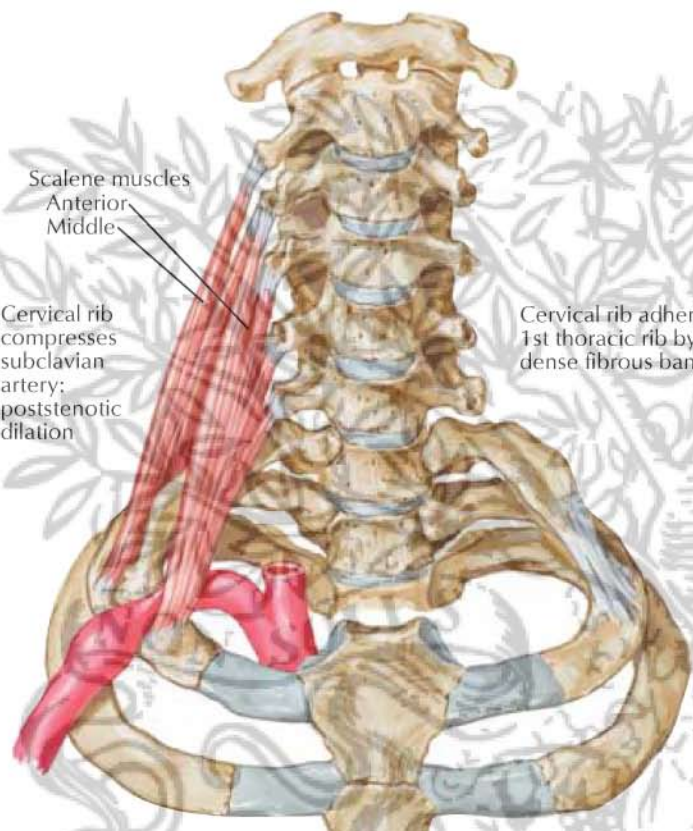
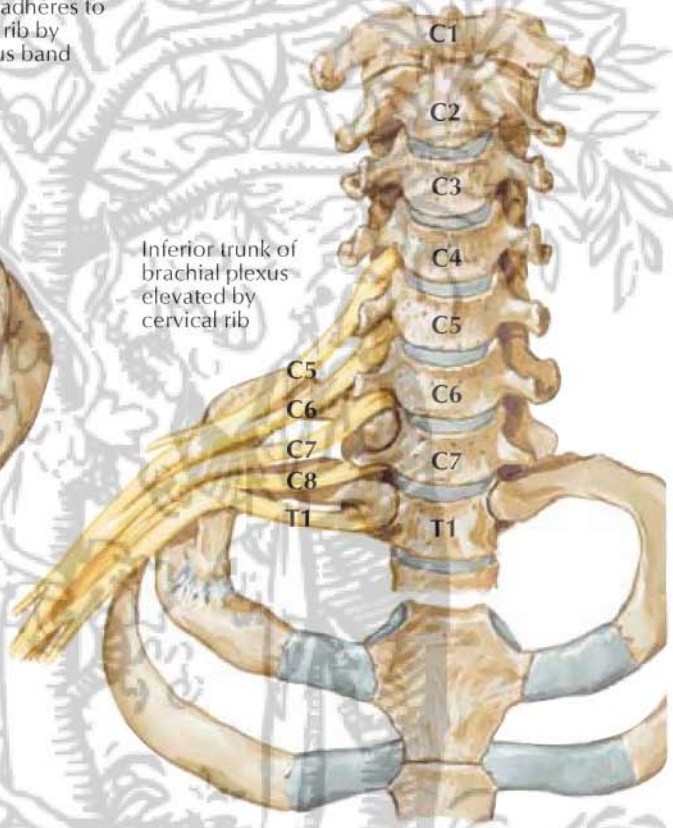


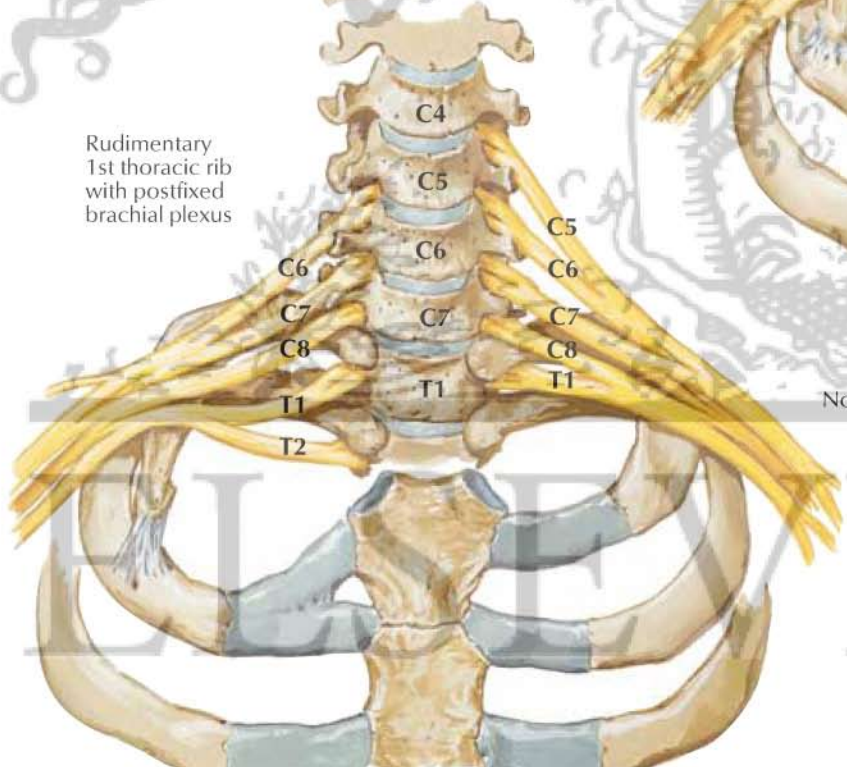
# Cervical Ribs and Related Anomalies



Cervical rib adheres to 1st thoracic rib by dense fibrous band



Rudimentary 1st thoracic rib with postfixed brachial plexus



Normal morphology

*F. Netter M.D.*