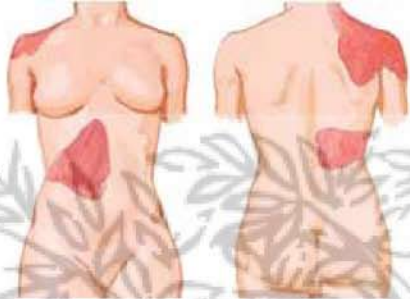
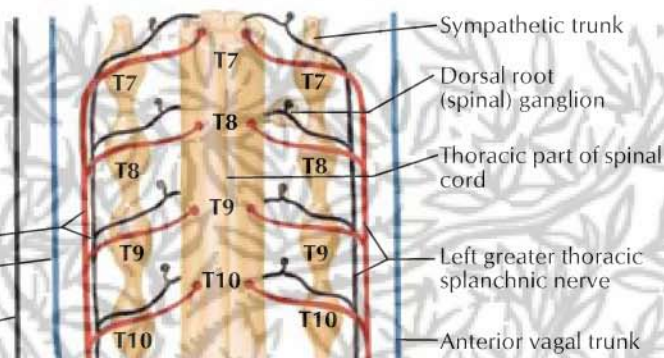


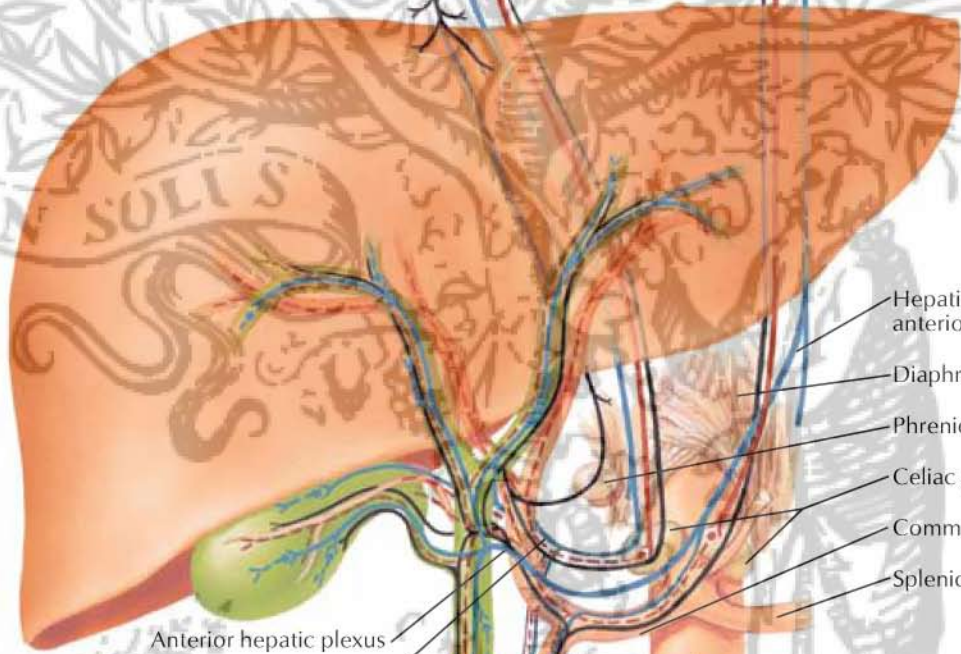Common areas of referred pain in biliary disease



Right greater thoracic splanchnic nerve
 Posterior vagal trunk
 Right phrenic nerve to diaphragmatic part of parietal (and visceral?) peritoneum



Sympathetic trunk
 Dorsal root (spinal) ganglion
 Thoracic part of spinal cord
 Left greater thoracic splanchnic nerve
 Anterior vagal trunk



Anterior hepatic plexus
 Posterior hepatic plexus

Hepatic branch of anterior vagal trunk
 Diaphragm
 Phrenic ganglion
 Celiac ganglia
 Common hepatic artery
 Splenic artery

Aorta
 Gastroduodenal artery and plexus

Sphincter of hepatopancreatic ampulla

Sympathetic fibers
 Preganglionic ——— (red solid line)
 Postganglionic - - - - (red dashed line)

Parasympathetic fibers
 Preganglionic ——— (blue solid line)
 Postganglionic - - - - (blue dashed line)

Afferent fibers ——— (black solid line)

Ramification of nerve fibers around fine branch of hepatic artery

