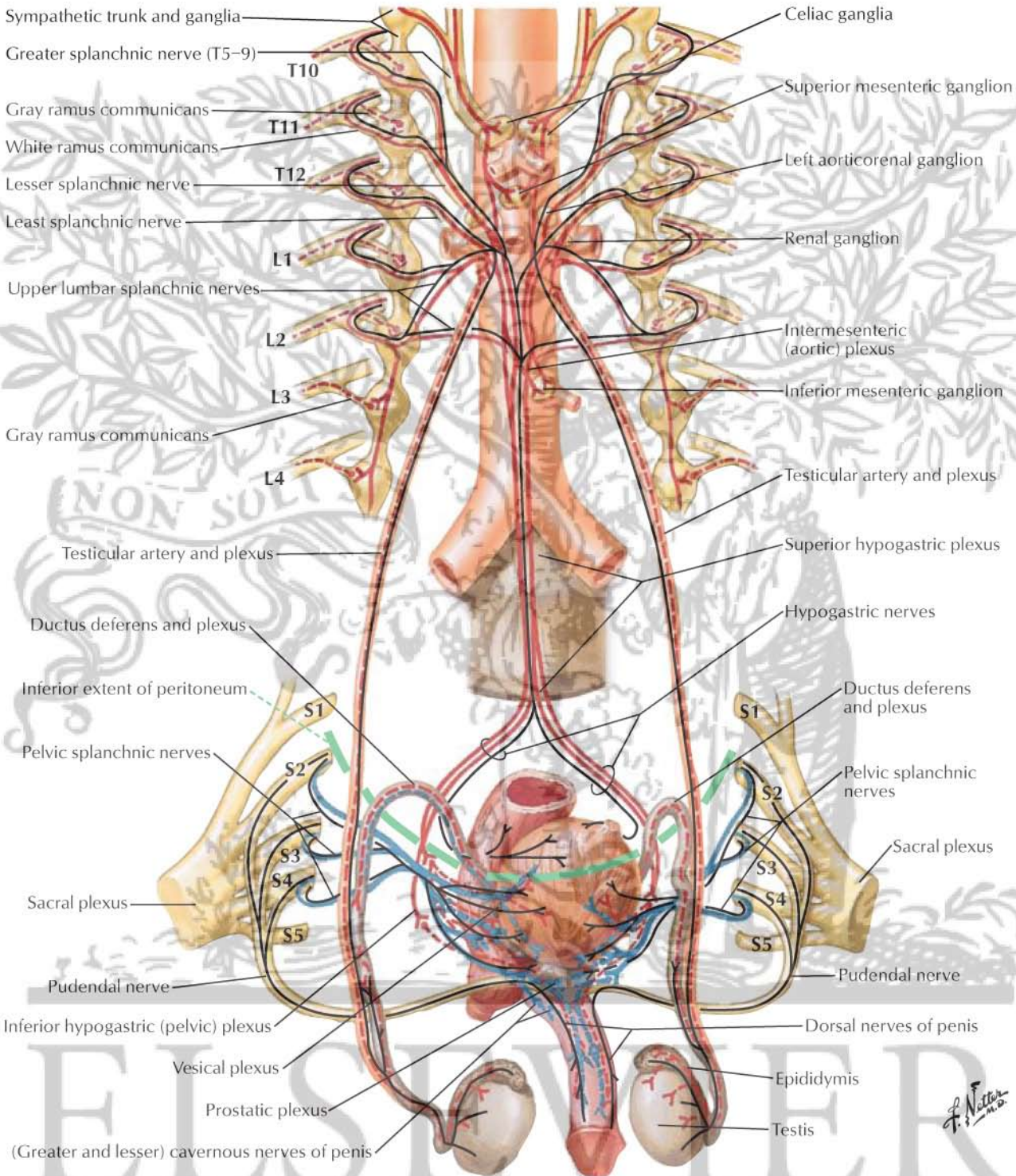


# Innervation of Male Reproductive Organs: Schema



Sympathetic fibers	{ Presynaptic ——— Postsynaptic - - - -	Parasympathetic fibers	{ Presynaptic ——— Postsynaptic - - - -	Afferent fibers ———