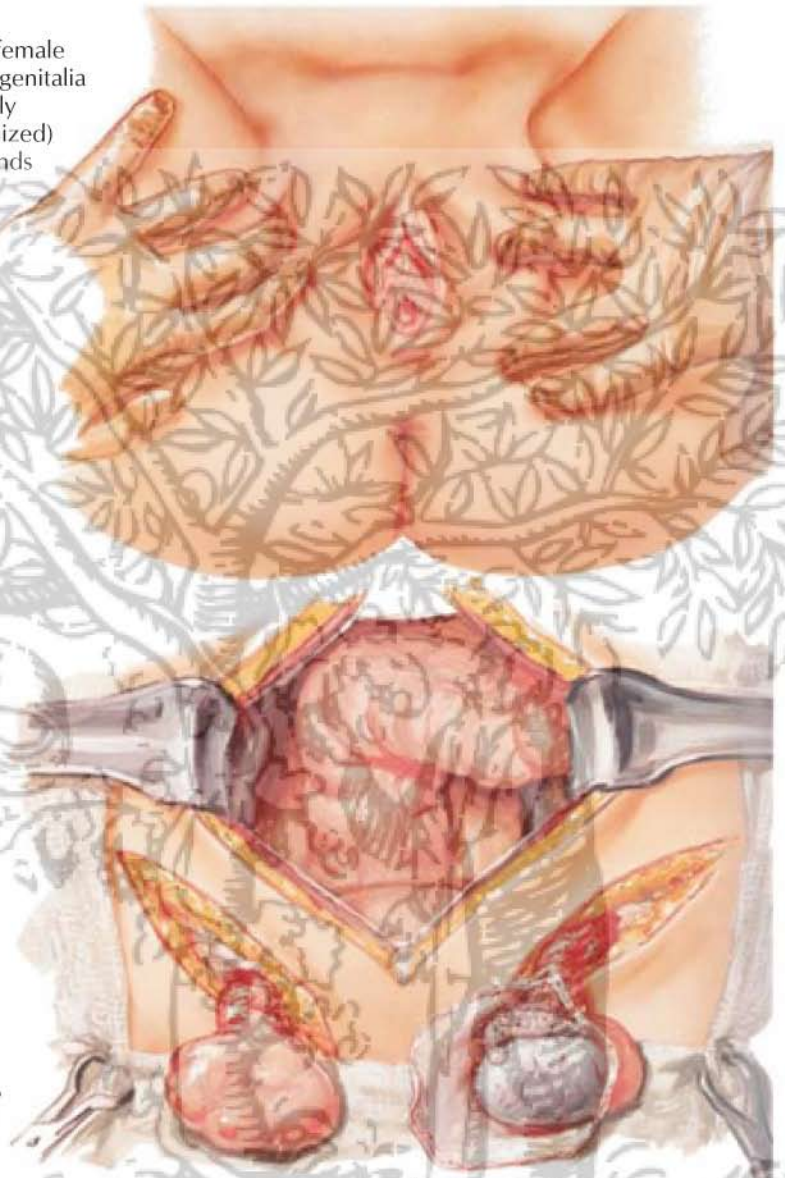

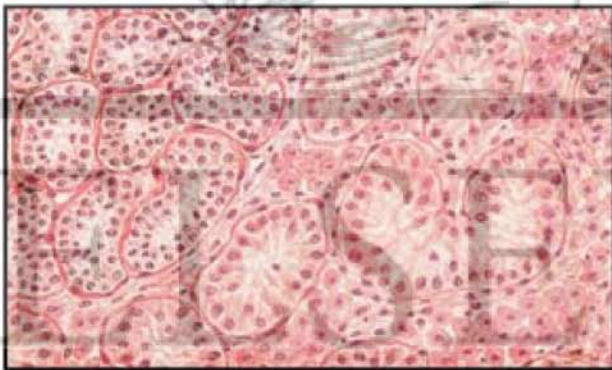
Normal female external genitalia (or slightly masculinized) vagina ends blindly.

Relatively normal female habitus (inguinal herniae)

*J. Netter M.D.*



Testes operatively exposed in groins; laparotomy reveals complete absence of uterus, fallopian tubes and ovaries



Section of testis typical of cryptorchidism (adenoma in upper left corner)

Negative (male) nuclear chromatin, XY (male) chromosomal pattern

