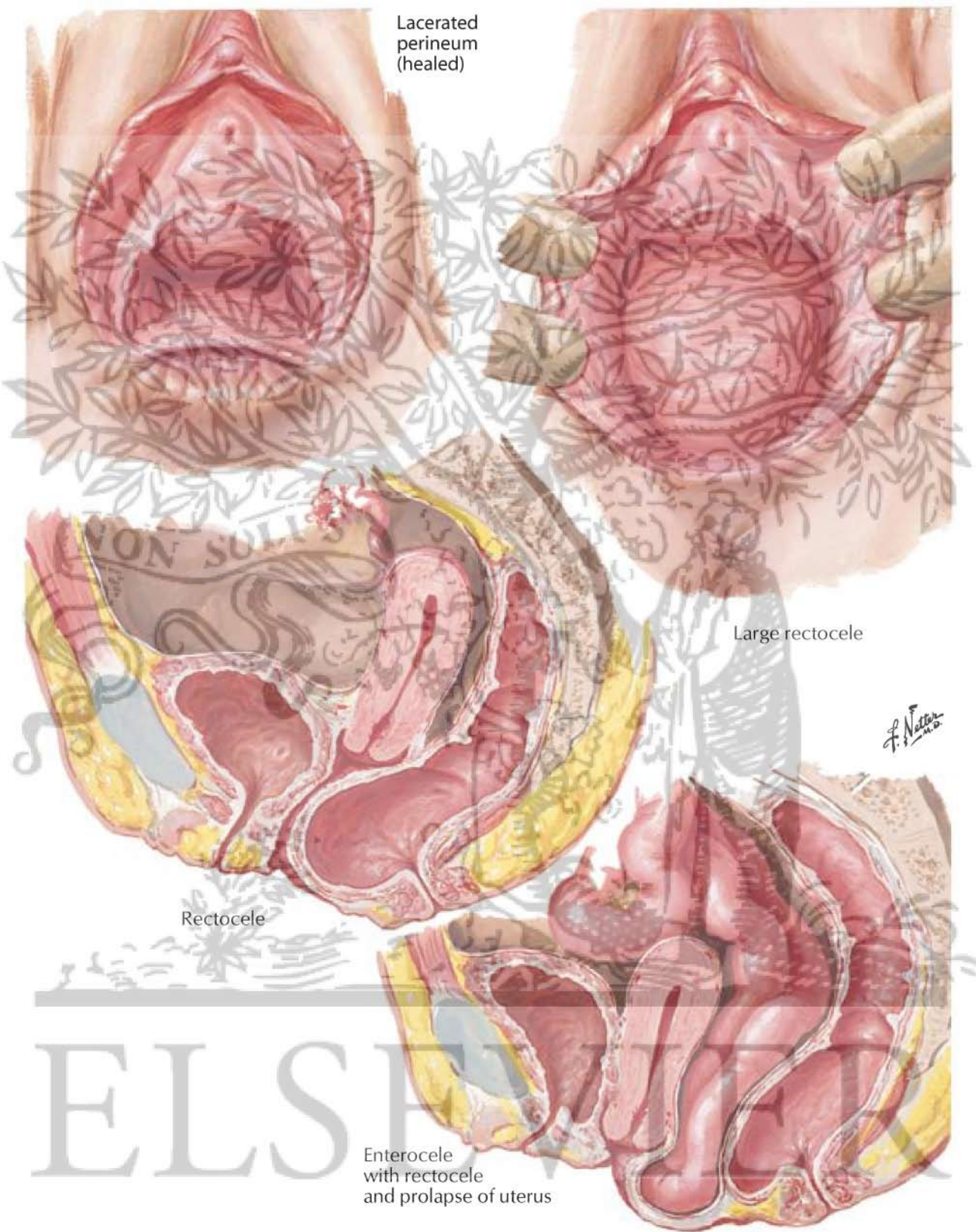


Lacerated
perineum
(healed)



Large rectocele

Rectocele

Enterocele
with rectocele
and prolapse of uterus