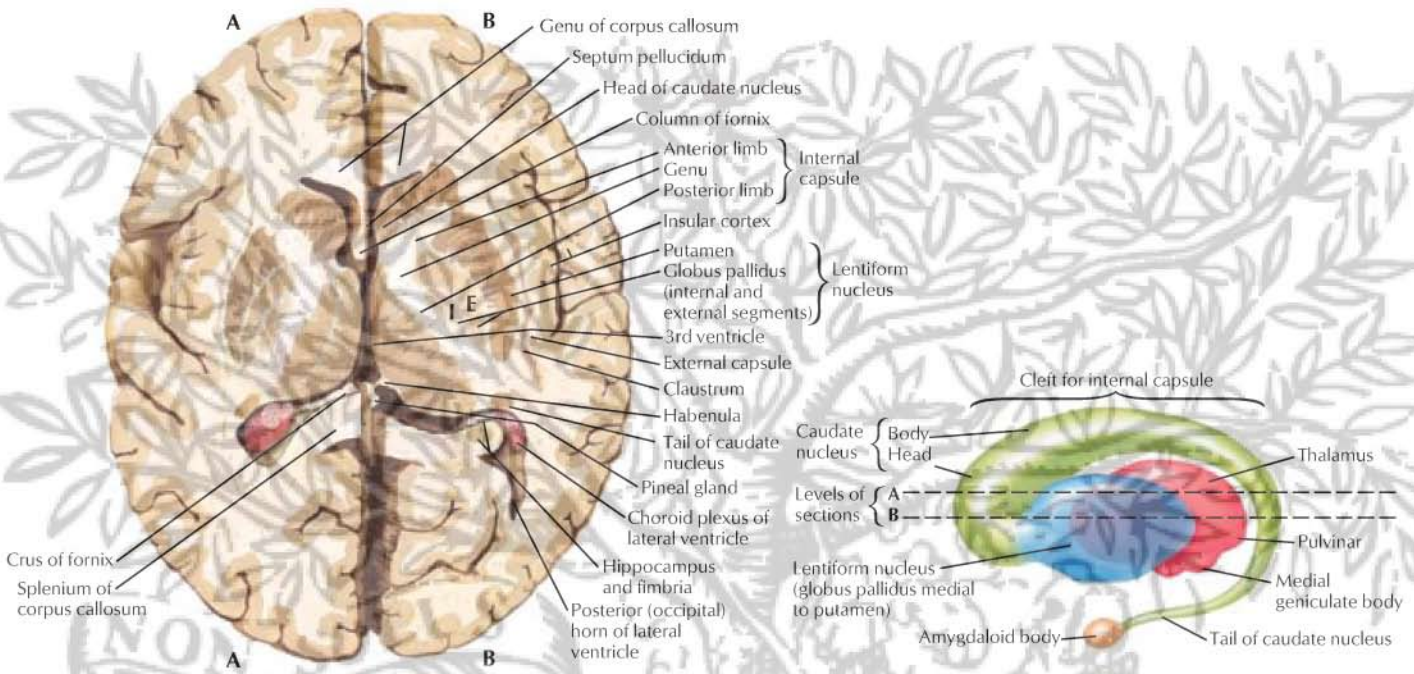
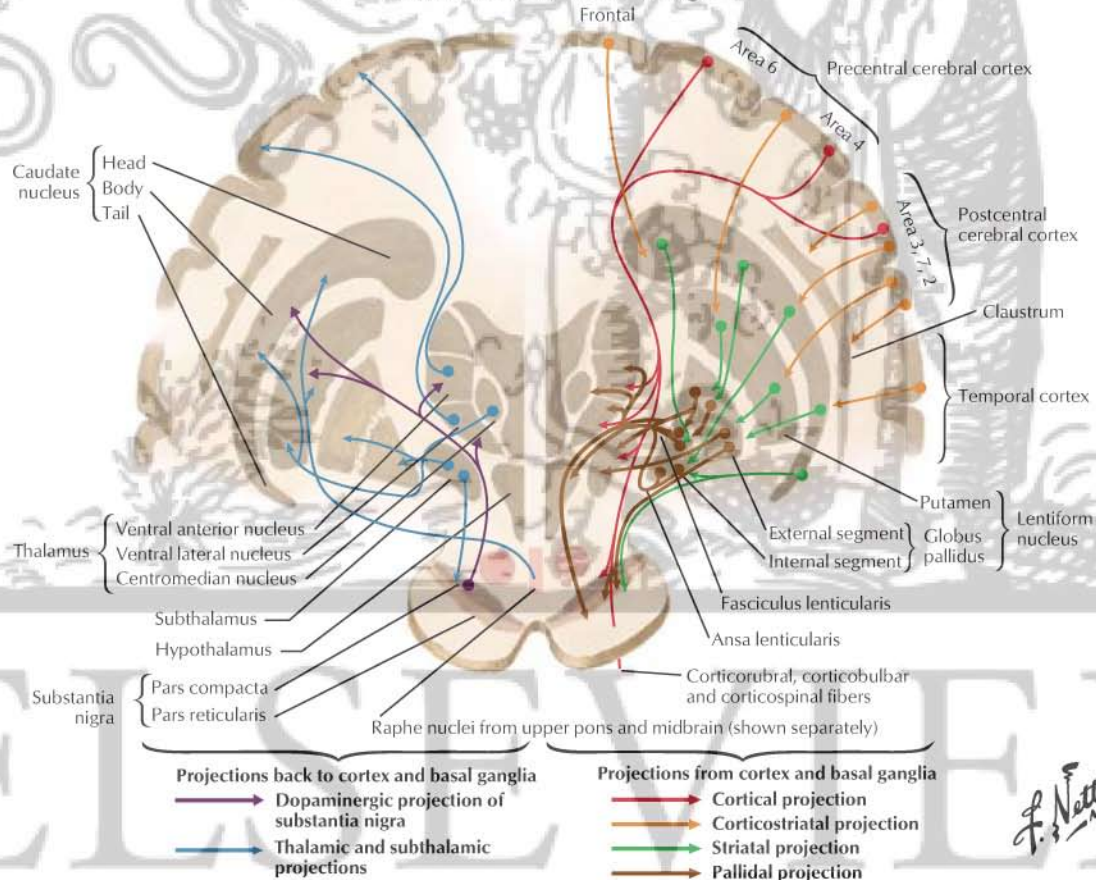


Horizontal Brain Section Showing Basal Ganglia



Connections of Basal Ganglia



F. Netter M.D.