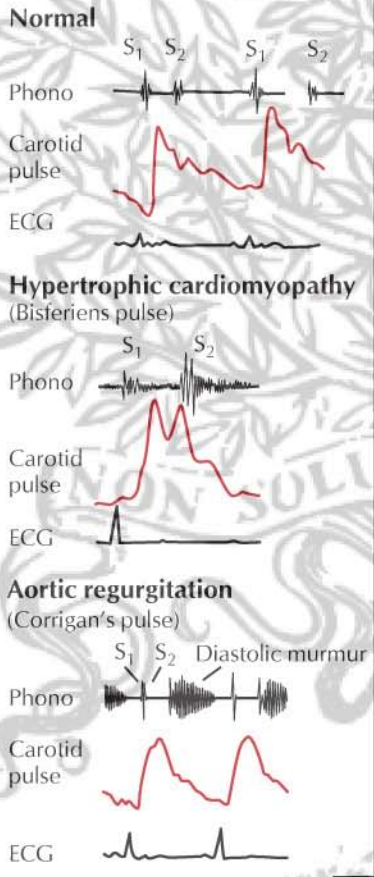
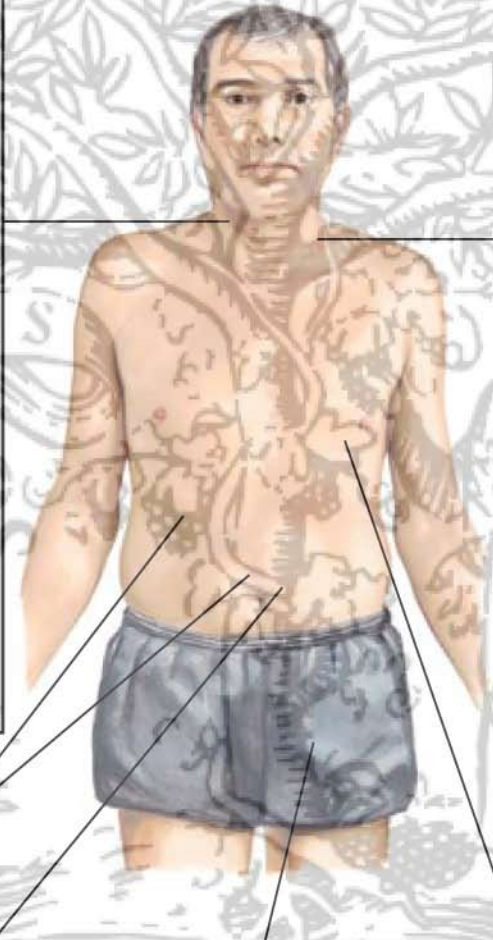
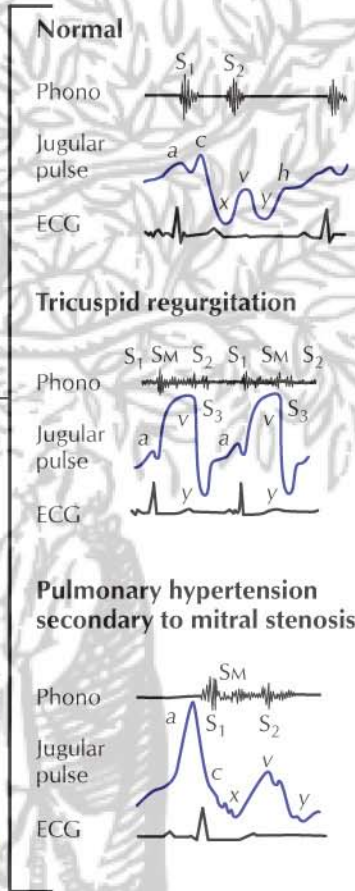


Important Components of Cardiac Examination

Examples of carotid pulses and the entities with which they are associated



Examples of venous pulses and the entities with which they are associated



C. Machado M.D.

Careful auscultation of the abdomen can reveal bruits from vessels such as aorta and renal arteries.

Dilatation of the abdominal portion of the aorta can be recognized by palpation.

Diminished or absent peripheral pulses indicate peripheral vascular disease.

Cardiac apical impulse (palpation of the precordium)

