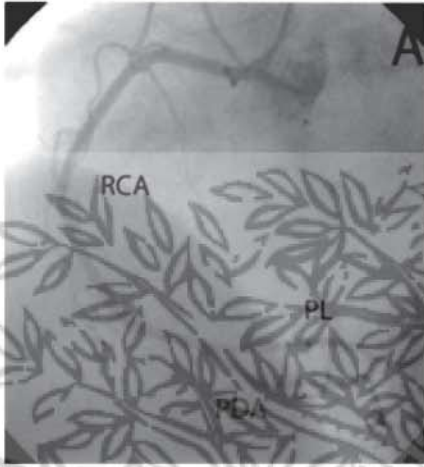
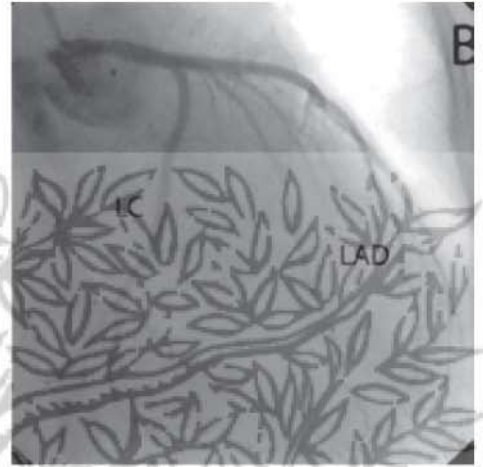


Coronary Angiography




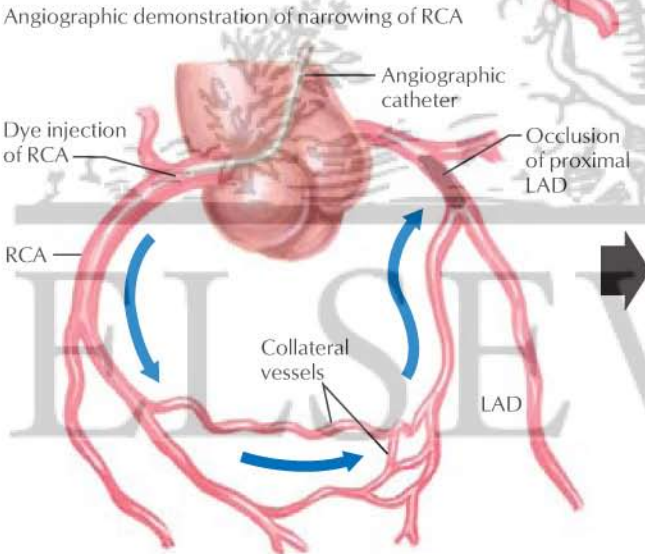
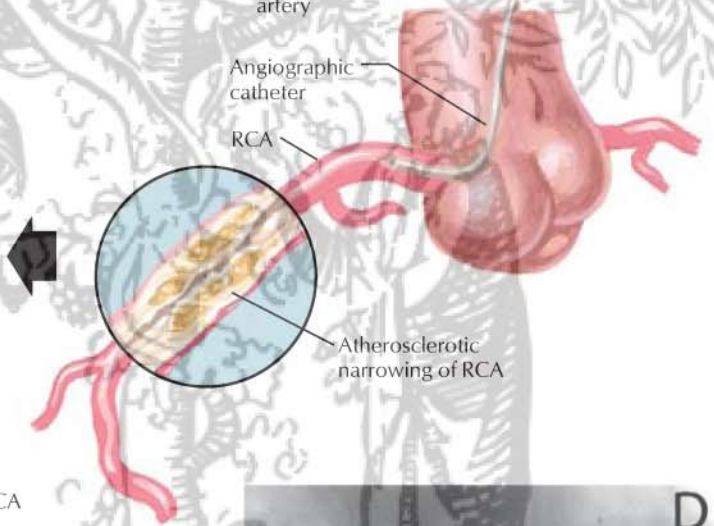
Angiogram of normal right coronary artery (RCA) and normal posterolateral (PL) and posterior descending (PDA) branches



Angiogram of normal left anterior descending coronary artery (LAD) and left circumflex (LC) artery



Angiographic demonstration of narrowing of RCA



Angiogram demonstrating filling of LAD by dye injected into RCA via collateral vessels

JOHN A. CRAIG MD