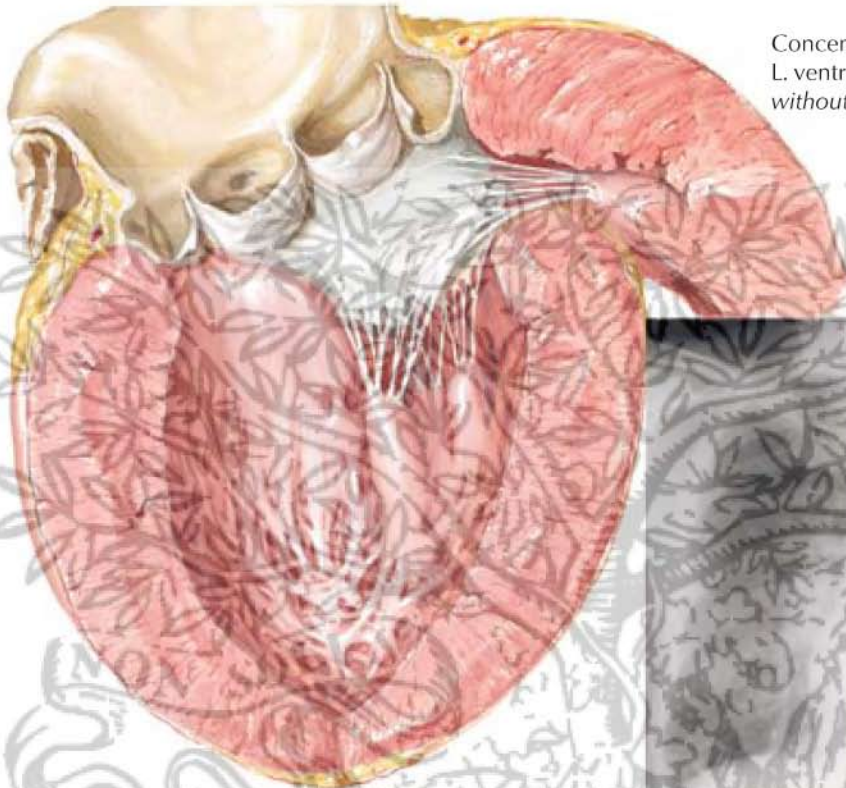
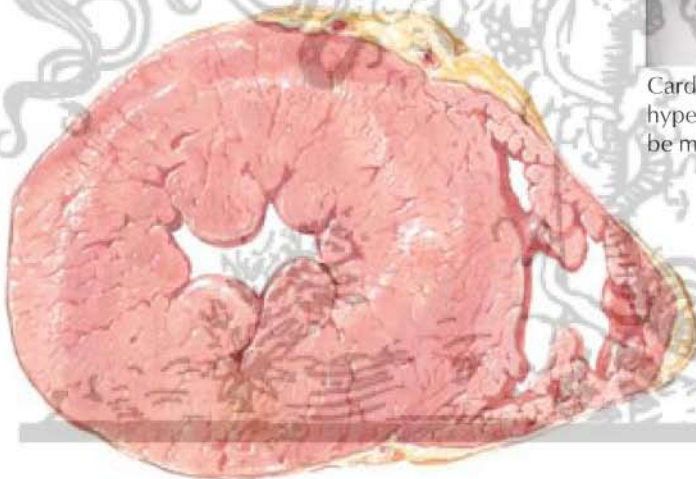


Heart Disease in Hypertension

Concentric hypertrophy of L. ventricle in hypertension *without* cardiac failure

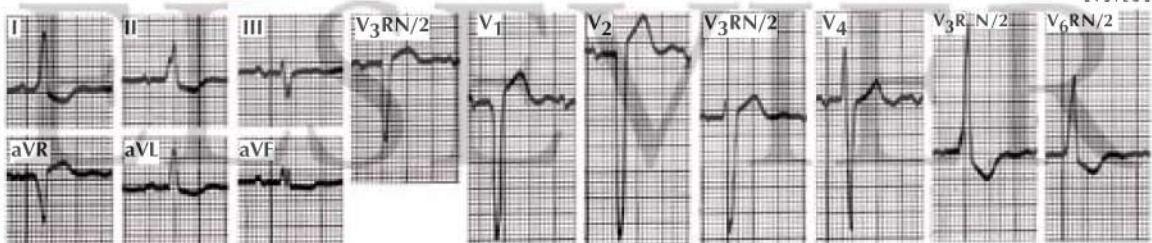


Cardiac hypertrophy in chronic hypertension (x-ray evidence may be minimal)



Cross-section of heart with greatly hypertrophied L. ventricle and relatively normal R. ventricle in uncomplicated hypertensive heart disease

F. Netter M.D.



Electrocardiographic evidence of L. ventricular hypertrophy may or may not be present (tall R waves in V₄, V₅, and V₆; deep S waves in V_{3R}, V₁, V₂, III, and aVR; depressed ST and inverted T in V₅, V₆, I, II, aVL, and aVF)