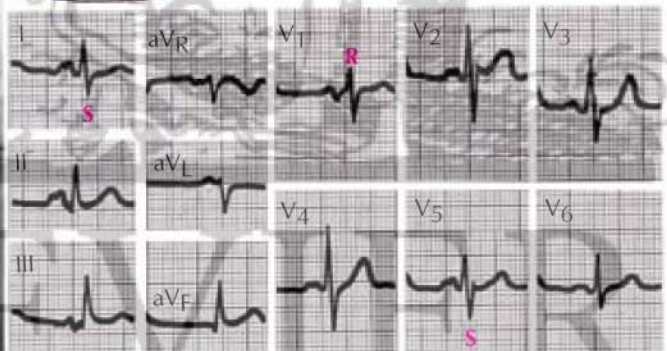
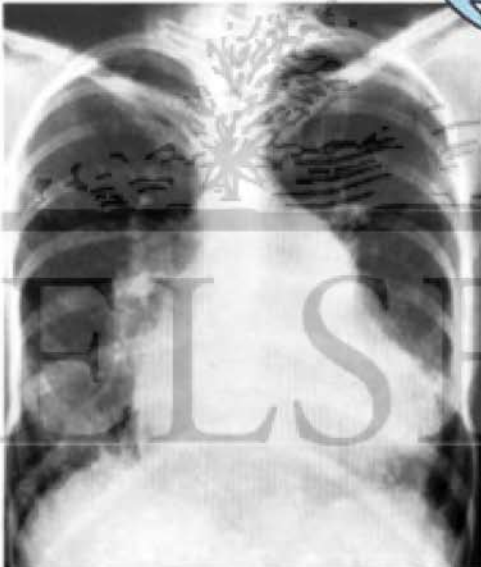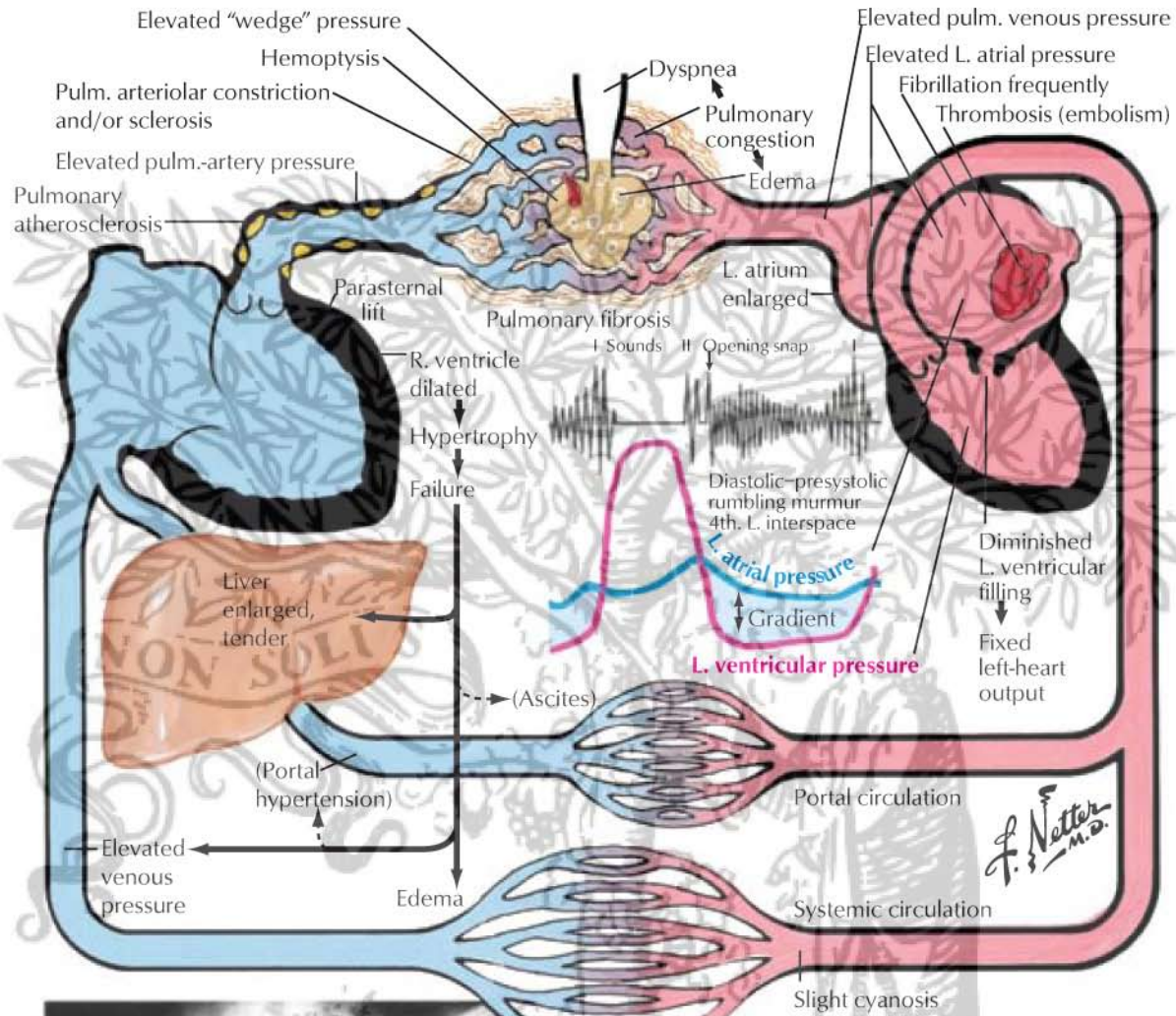


# Pathophysiology and Clinical Aspects of Mitral Stenosis



L. atrial abnormality (P "mitral") and evidence of R. ventricular hypertrophy (S in leads I and V5, R in V1)

