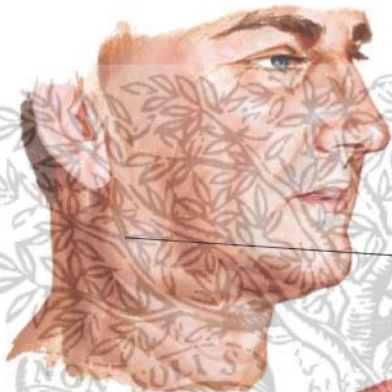
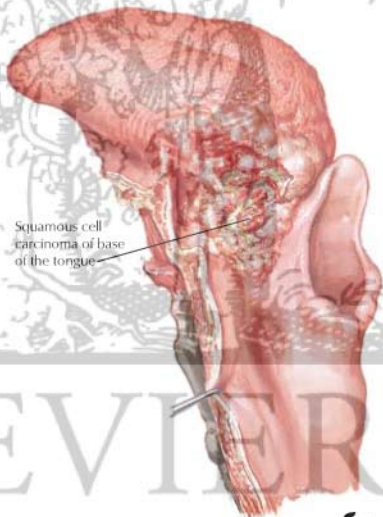


# Malignant Tumors of Oropharynx



Enlarged cervical node  
often initial sign in  
malignancies of the  
oropharynx



Squamous cell  
carcinoma of base  
of the tongue

ELSEVIER

*F. Netter  
M.D.*