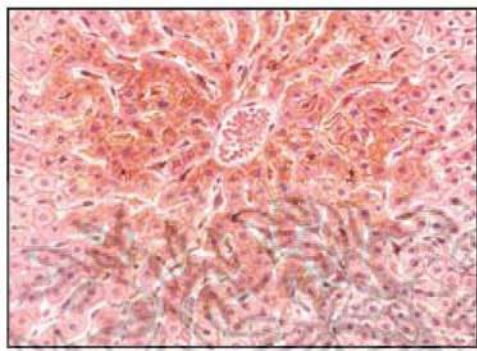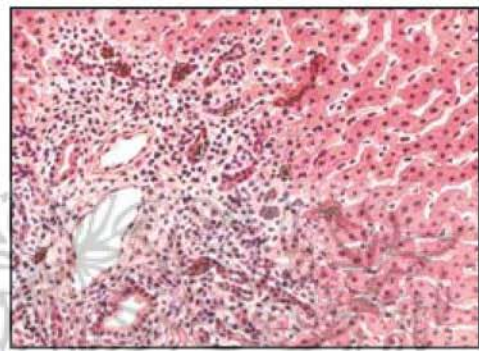

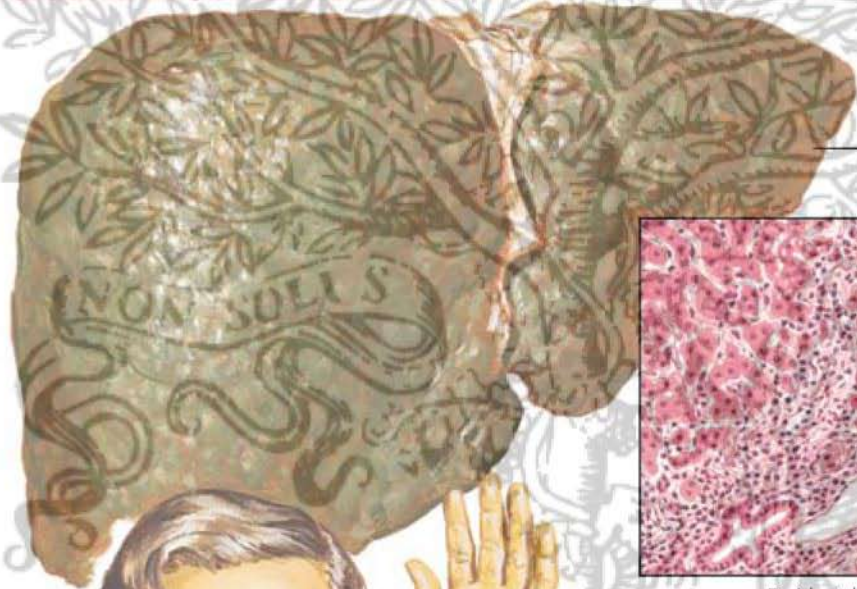
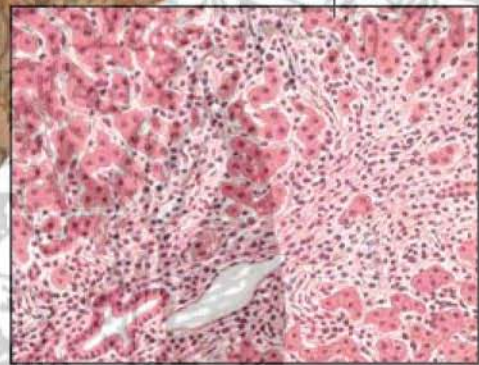
Centrilobular intrahepatic cholestasis




Portal inflammation and ductular proliferation



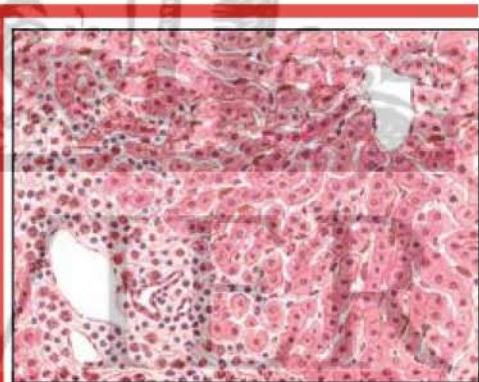
Primary biliary cirrhosis associated with cutaneous xanthomas



Periductal inflammation



Xanthomas of face, neck, palm and elbow



Portal inflammation "hypersensitivity"

*F. Netter M.D.*