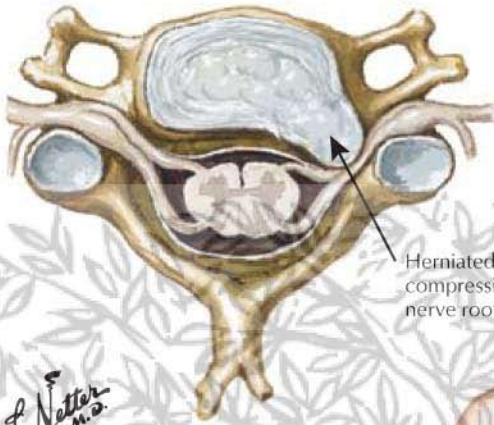
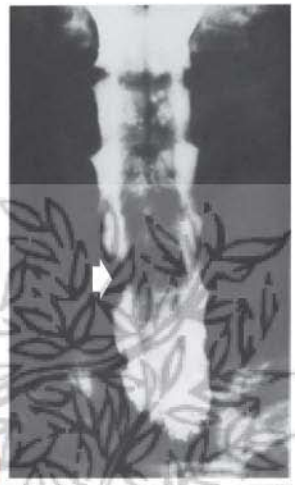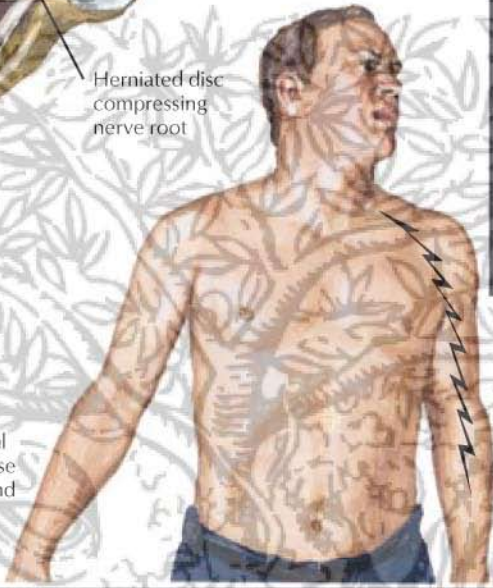


Cervical Disc Herniation: Clinical Manifestations



F. Netter M.D.

Spurling maneuver: hyperextension and flexion of neck ipsilateral to the side of lesion cause radicular pain in neck and down the affected arm



Myelogram (AP view) showing prominent extradural defect (open arrow) at C6-7

Level	Motor signs (weakness)	Reflex signs	Sensory loss
C5	<p>Deltoid</p>	<p>0</p>	
C6	<p>Biceps brachii</p>	<p>Biceps brachii</p> <p>Weak or absent reflex</p>	
C7	<p>Triceps brachii</p>	<p>Triceps brachii</p> <p>Weak or absent reflex</p>	
C8	<p>Interossei</p>	<p>0</p>	