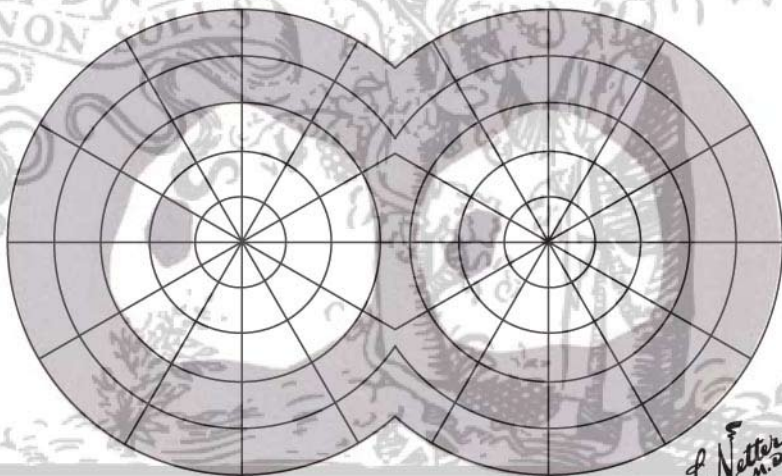


Optic fundus with papilledema



Visual field changes with enlarged blind spots secondary to chronic papilledema

*F. Netter M.D.*