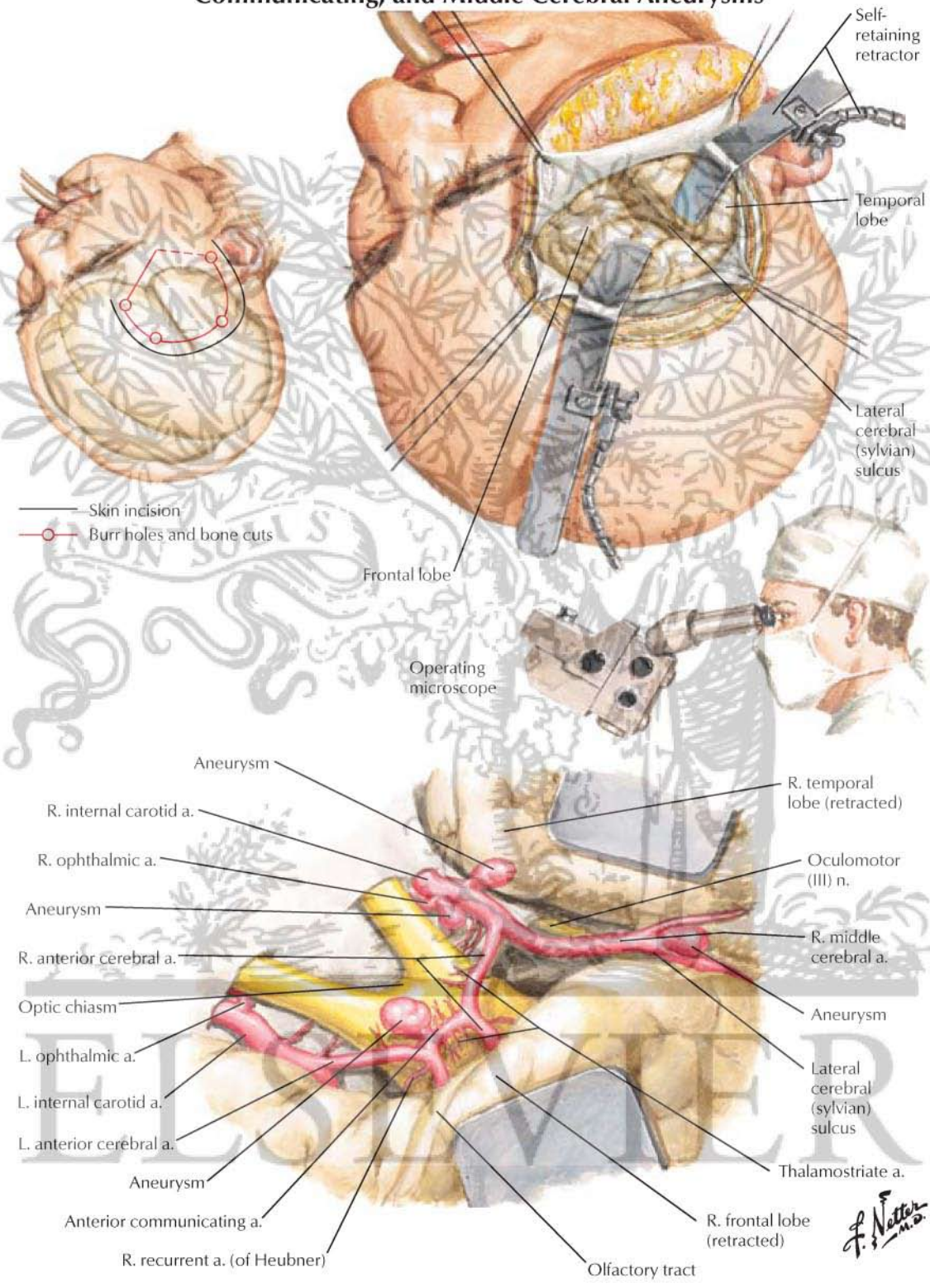


Frontotemporal Approach for Internal Carotid, Ophthalmic, Anterior Communicating, and Middle Cerebral Aneurysms



F. Netter M.D.