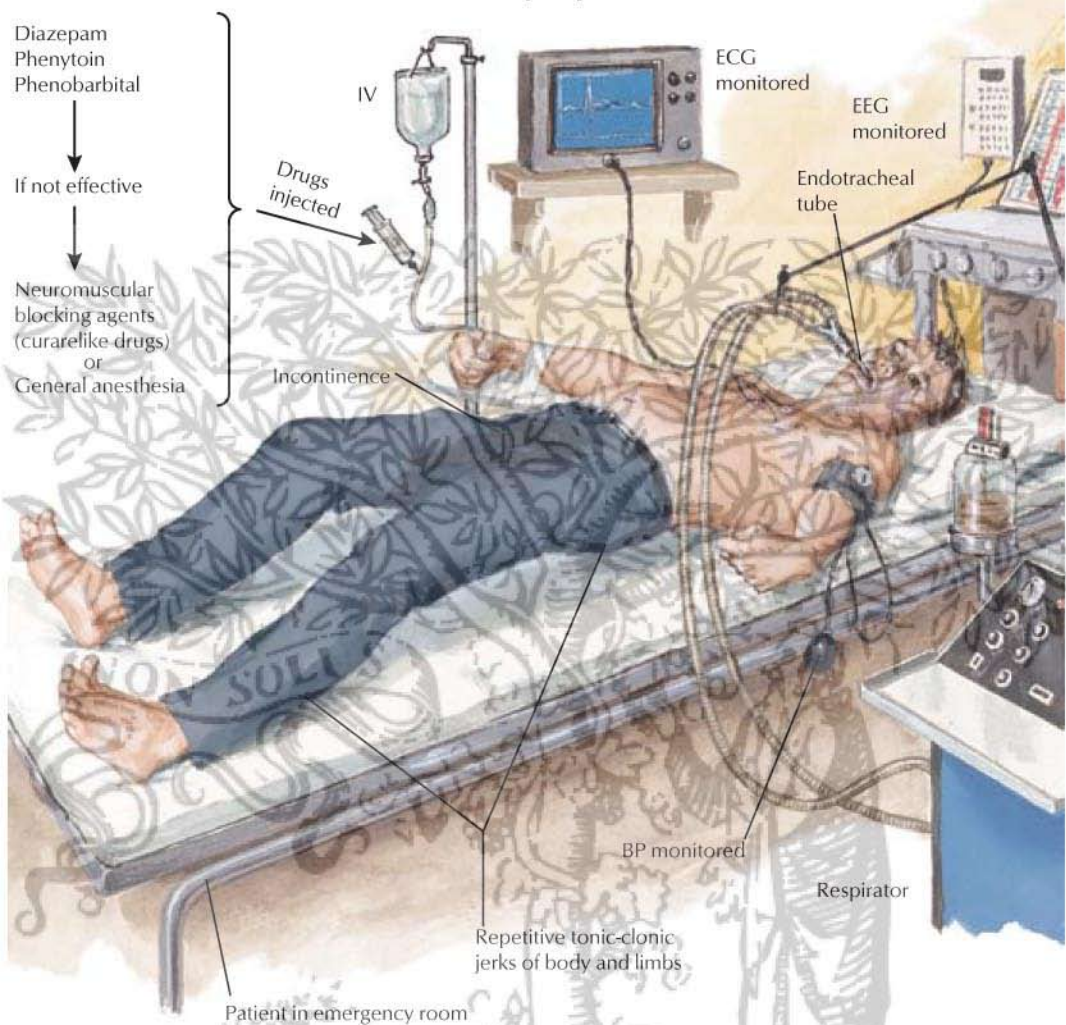
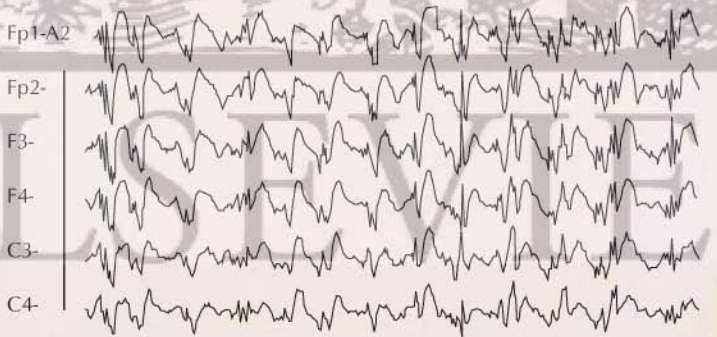


Status Epilepticus



EEG: status epilepticus



Continuous repetitive generalized spike-and-wave discharges

100 μ V
1 sec

F. Netter M.D.