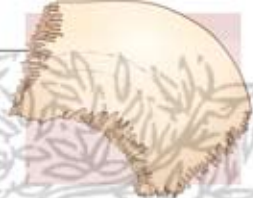
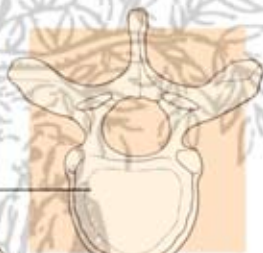


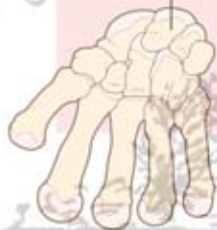Long bone
(humerus)



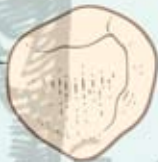Flat bone
(parietal)



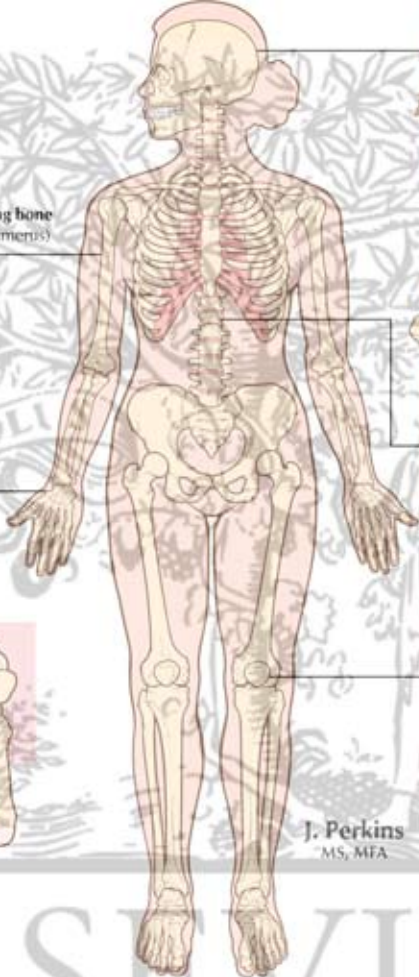
Irregular bone
(vertebra)



Short bones
(carpals)



Sesamoid bone
(patella)



J. Perkins
MS, MFA

ELSEVIER