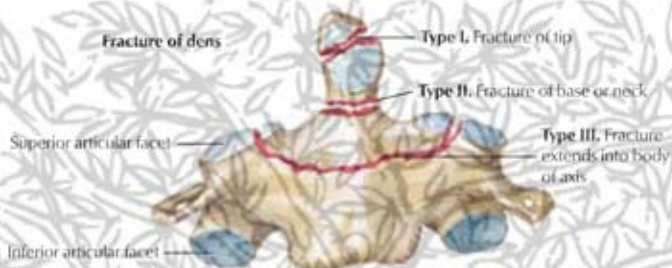


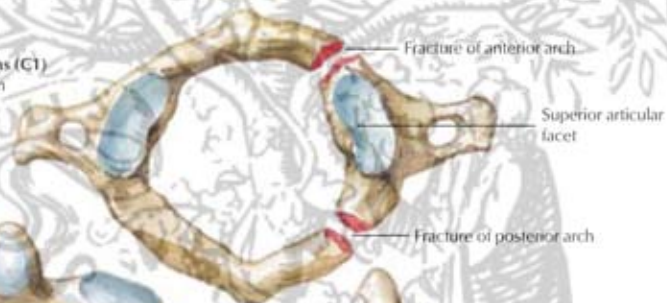
Fractures of cervical vertebrae

Fracture of dens

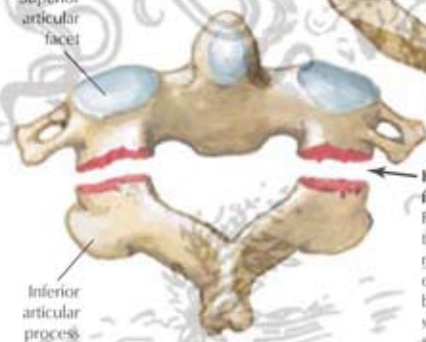


Jefferson fracture of atlas (C1)

Each arch may be broken in one or more places

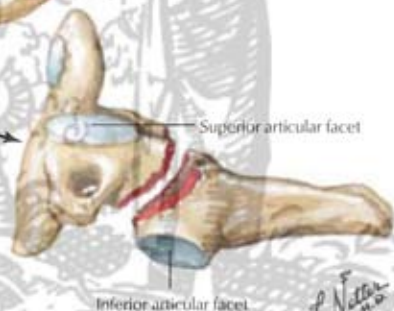

Superior articular facet



Hangman fracture

Fracture through neural arch of axis (C2), between superior and inferior articular facets



ELSEVIER