

Difficulty in arising from chair, often early complaint



Difficulty in raising arm to brush hair

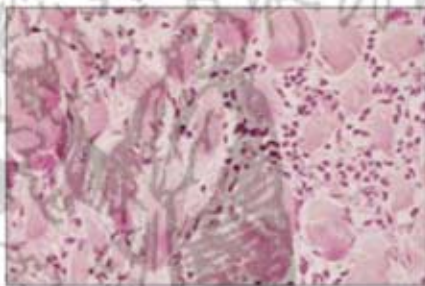


Dysphagia: aspiration of food may cause pneumonia



Edema and heliotrope discoloration around eyes a classic sign. More widespread erythematous rash may also be present

Muscle biopsy specimen: Transverse section



Normal

Polymyositis

