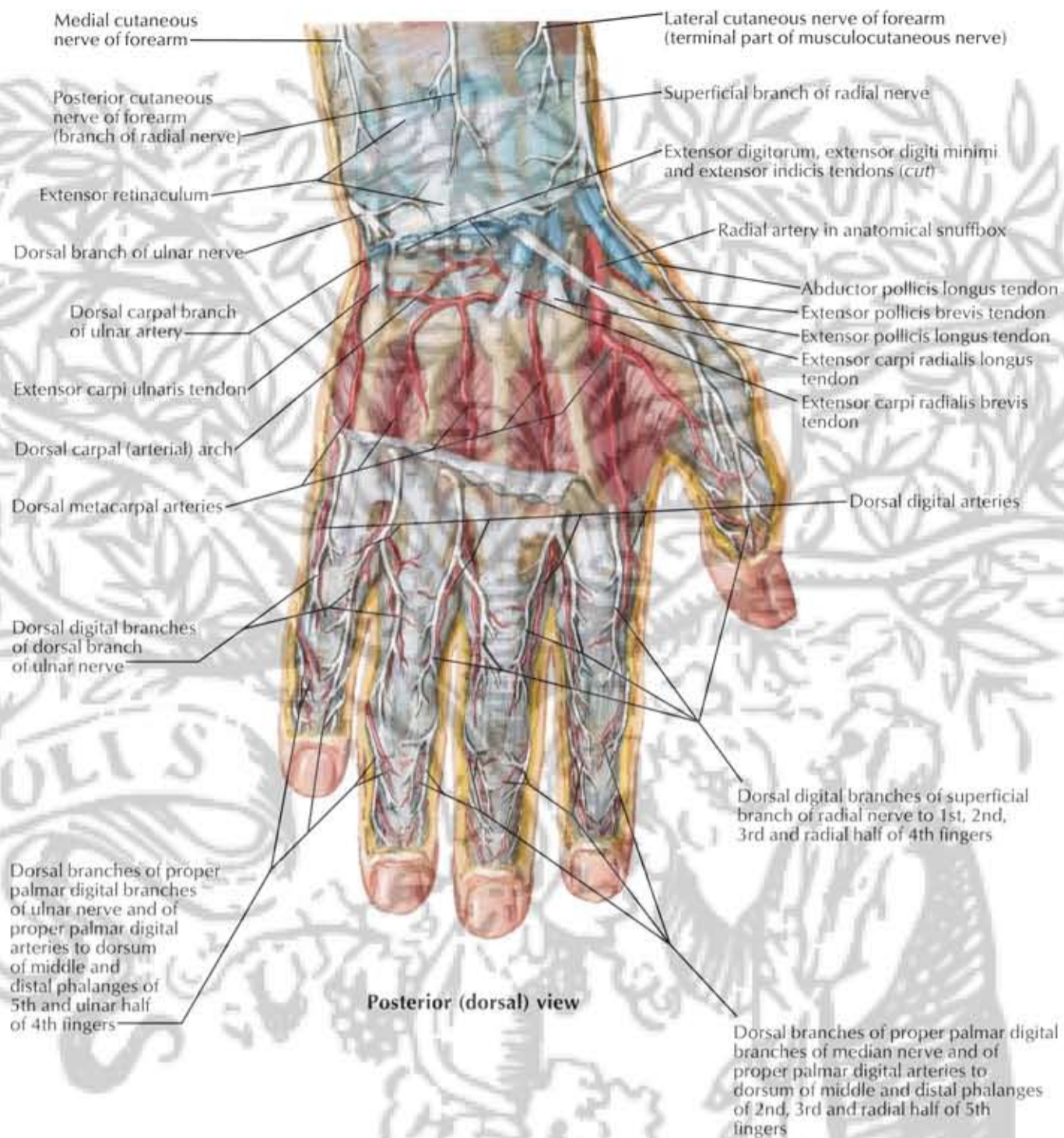
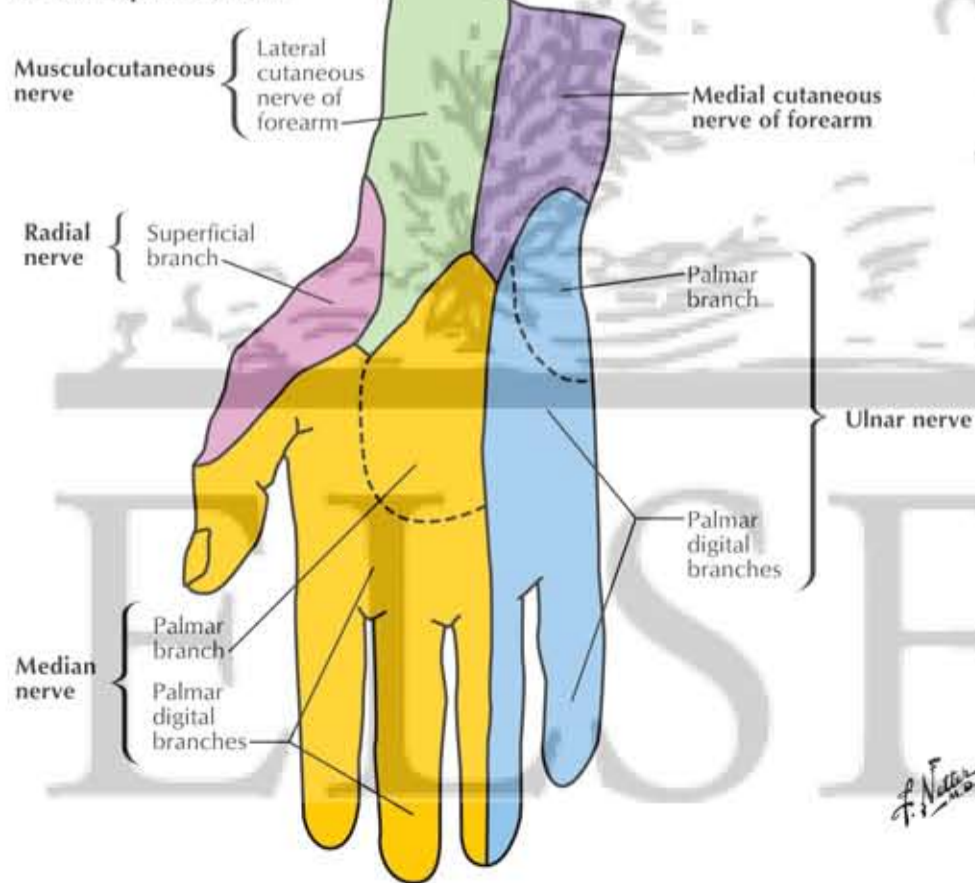


Wrist and Hand: Deep Dorsal Dissection



Cutaneous Innervation of Wrist and Hand

Anterior (palmar) view



Posterior (dorsal) view

