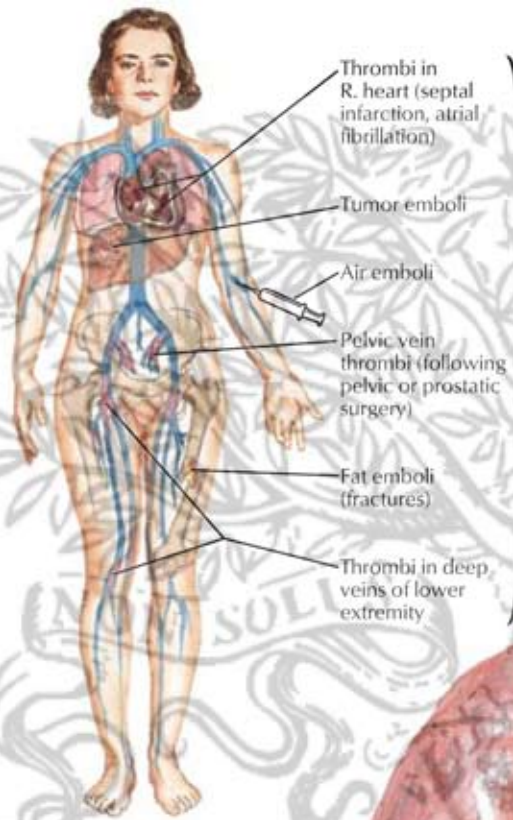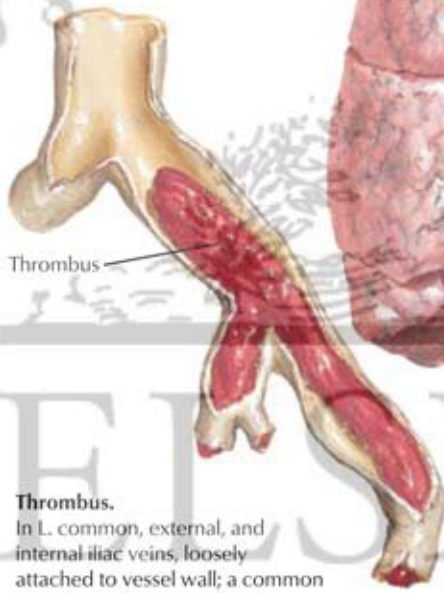
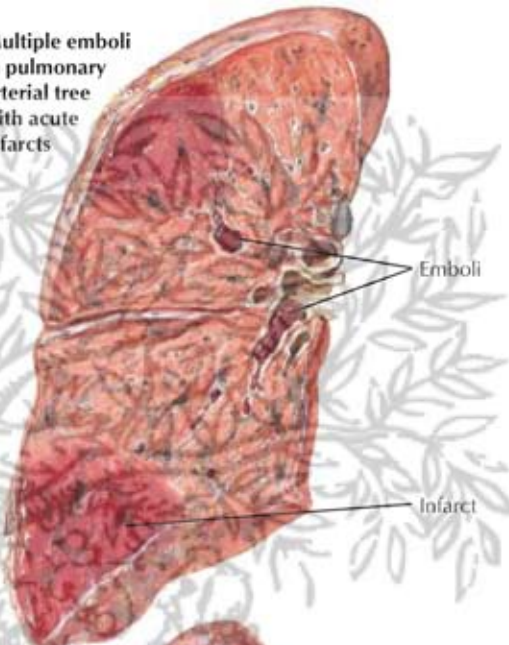
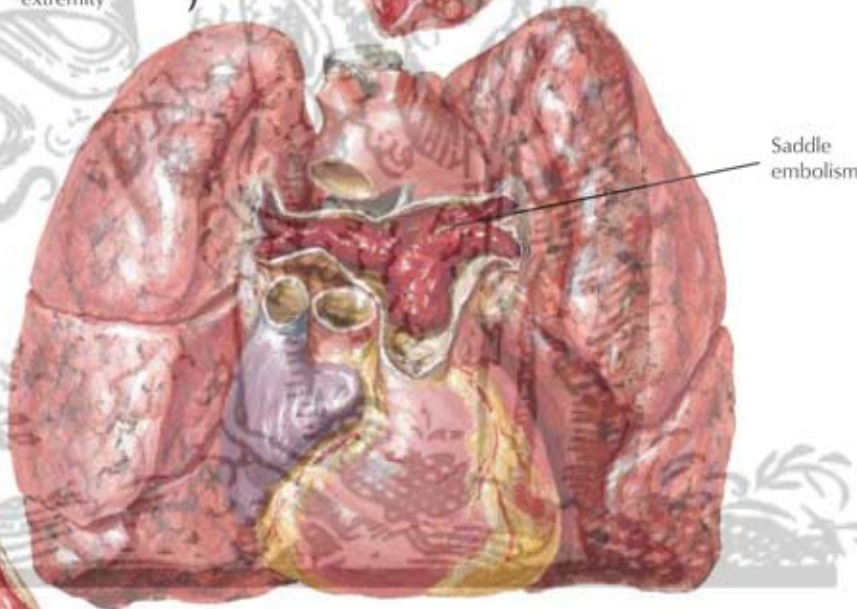


Sources of pulmonary emboli

Multiple emboli in pulmonary arterial tree with acute infarcts



**Thrombus.**  
In L. common, external, and internal iliac veins, loosely attached to vessel wall; a common source of pulmonary emboli



Massive embolism of pulmonary trunk and main pulmonary arteries. Without infarction; right heart dilated

*F. Netter M.D.*