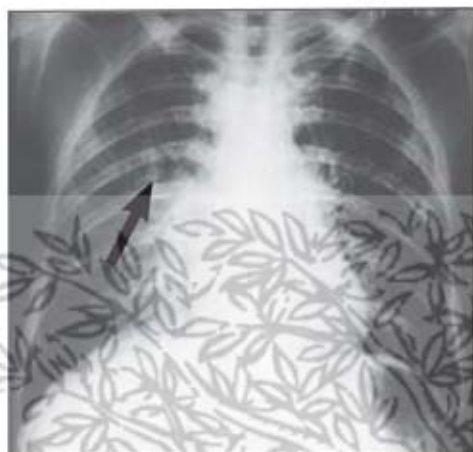


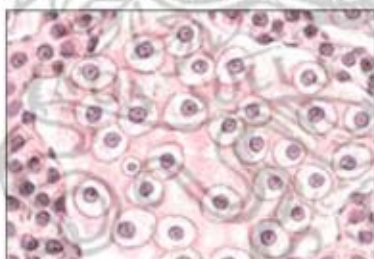
## Hypersensitivity Pneumonitis



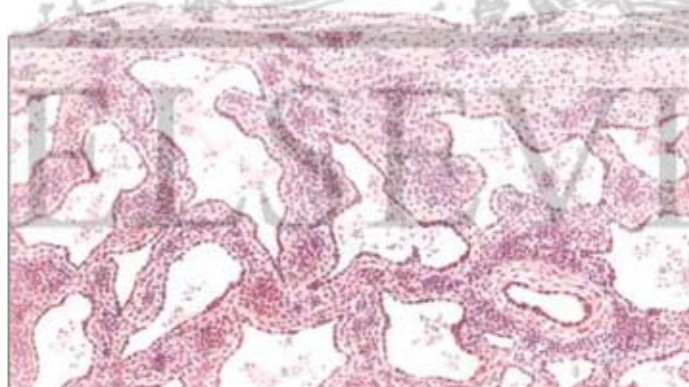
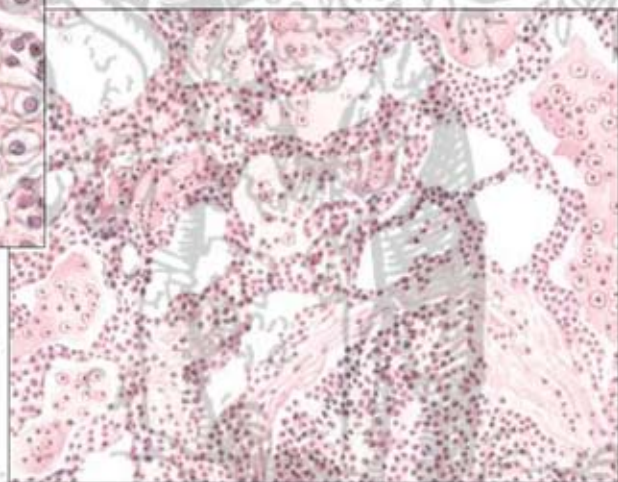
**Acute bagassosis.** Small nodular and miliary densities (arrow) throughout both lungs. Deposits may be more hazy and homogeneous in some cases.



**Chronic bagassosis.** Intense fibrosis and bullous emphysema after many episodes of respiratory illness during 9 years of industrial exposure.



**Tissue reaction in bagassosis.** Alveolar walls thickened with infiltrate of plasma cells and lymphocytes. Some alveolar spaces contain edema fluid and desquamated histiocytes with vacuolated cytoplasm. High-power section inset above shows macrophages with vacuolated cytoplasm filling alveolar space.



**Extensive subpleural and interalveolar fibrosis.** With inflammatory cell infiltration characteristic of advanced stage of farmer's lung (low-power section)