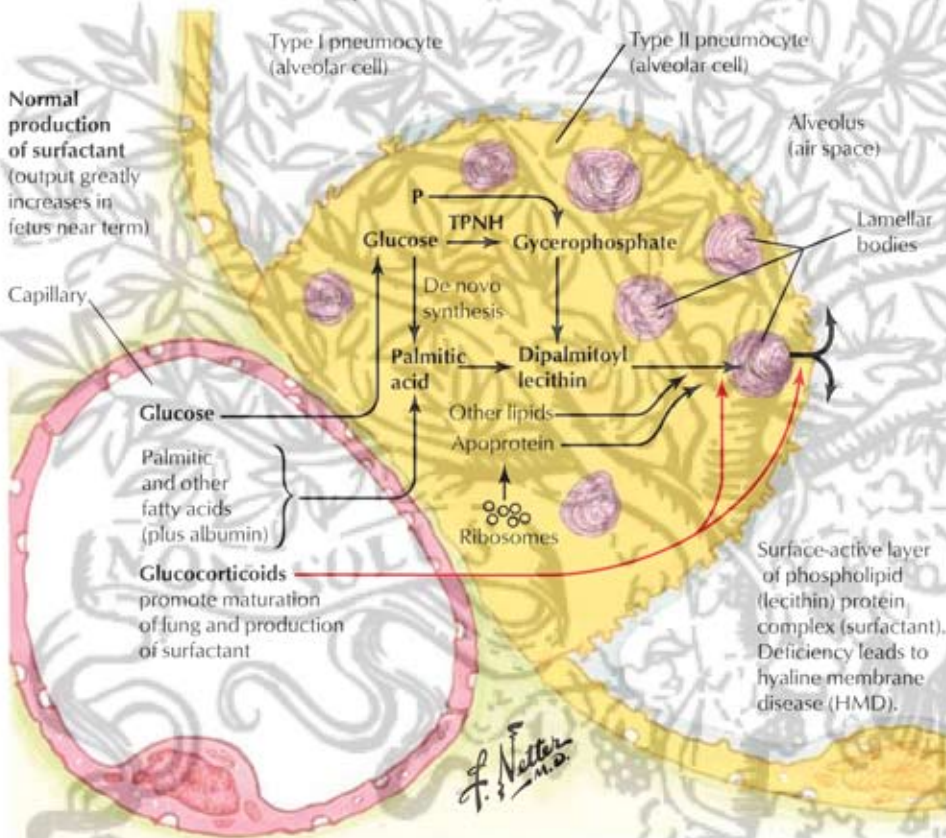
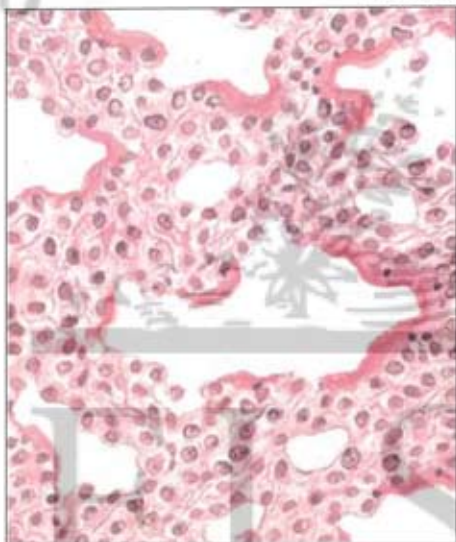


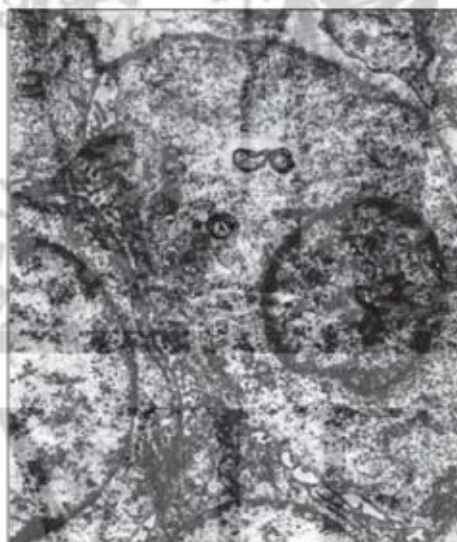Hyaline membrane disease



Pathology of hyaline membrane disease



Atelectasis. With eosinophilic hyaline membrane partially lining most peripheral air space.



Electron photomicrograph. Type II pneumocyte practically devoid of lamellar bodies.