

Complex Cystometry

Pressure readings




Intravesical (bladder) pressure (P_{ves})




Intra-abdominal pressure (P_{abd}) measured with vaginal probe



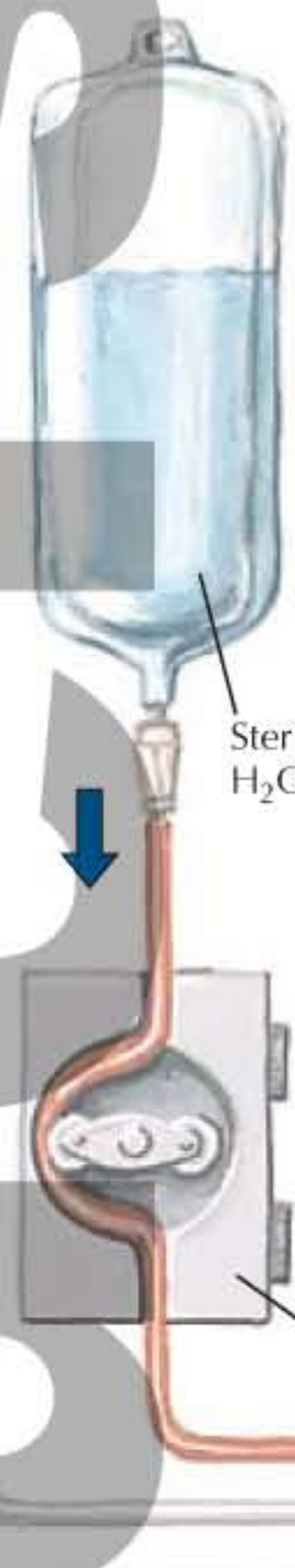
Intravesical pressure – intra-abdominal pressure = true detrusor pressure (P_{det})



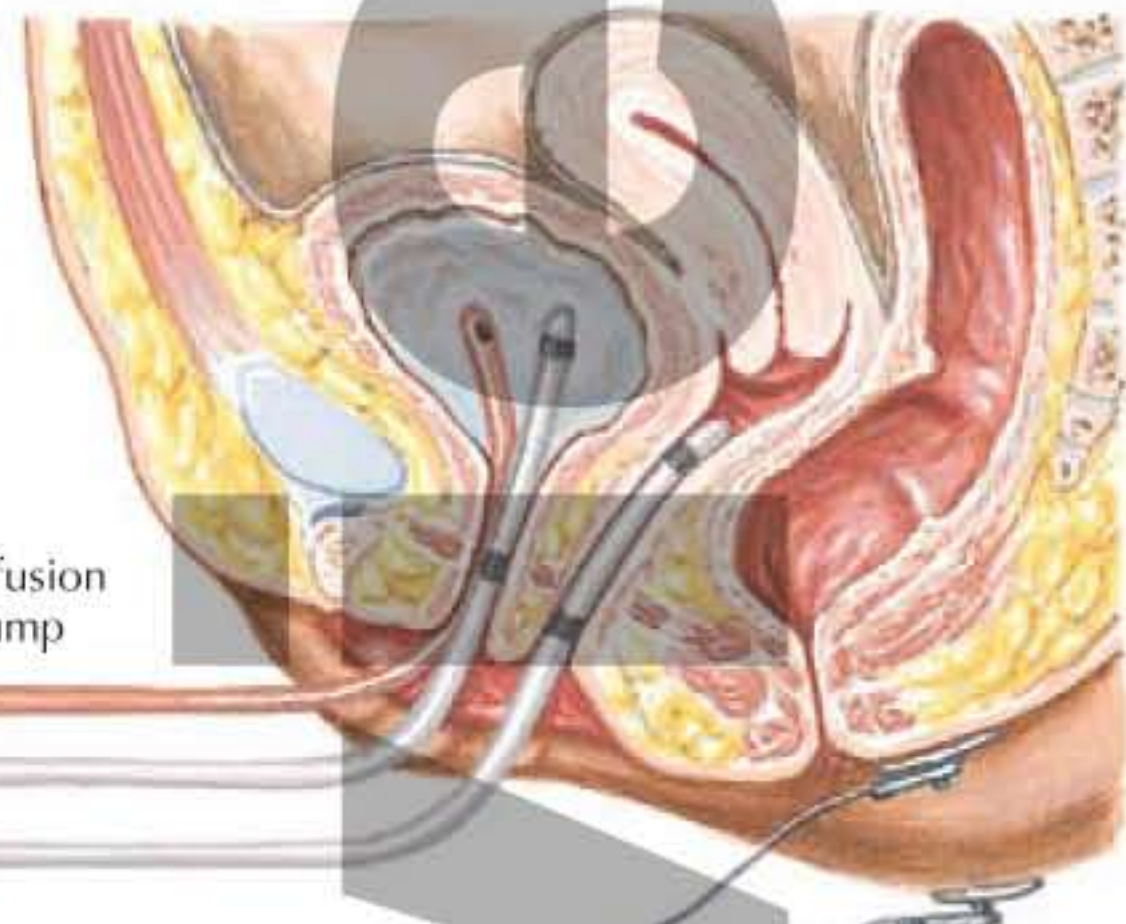
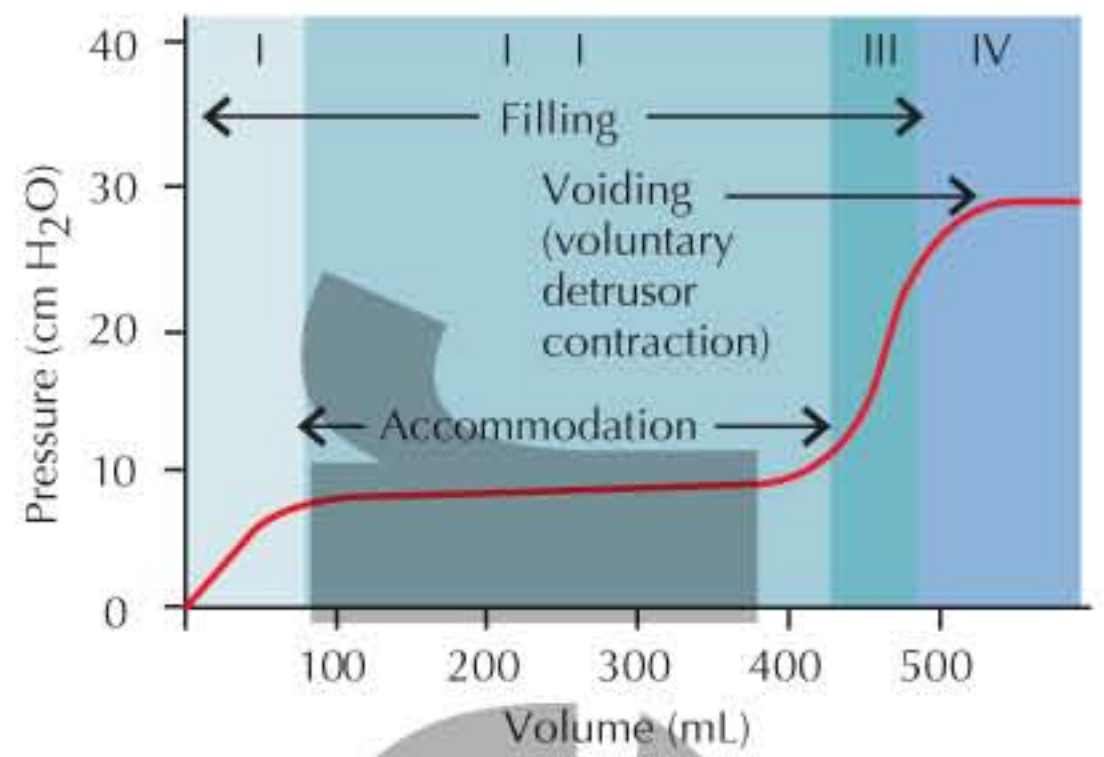
Intraurethral pressure (P_{ure})



Electromyography (EMG)

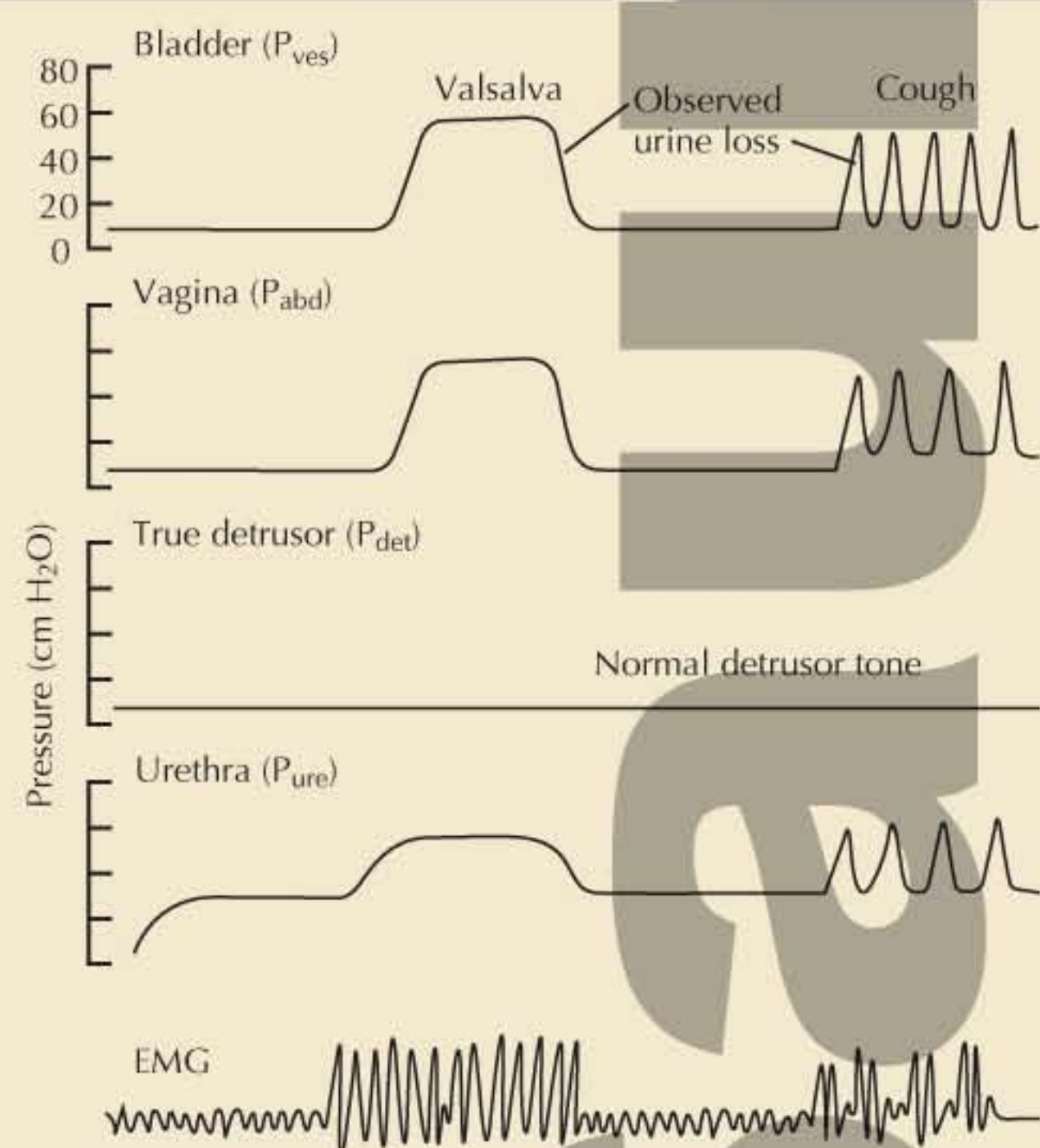


Normal bladder pressure/volume curve



Bladder volume increased steadily with retrograde infusion of H_2O while pressures and EMG activity monitored and urine loss observed

Stress incontinence



Detrusor instability

