

Dorsal scapular nerve (C5)

Suprascapular nerve (C5, 6)

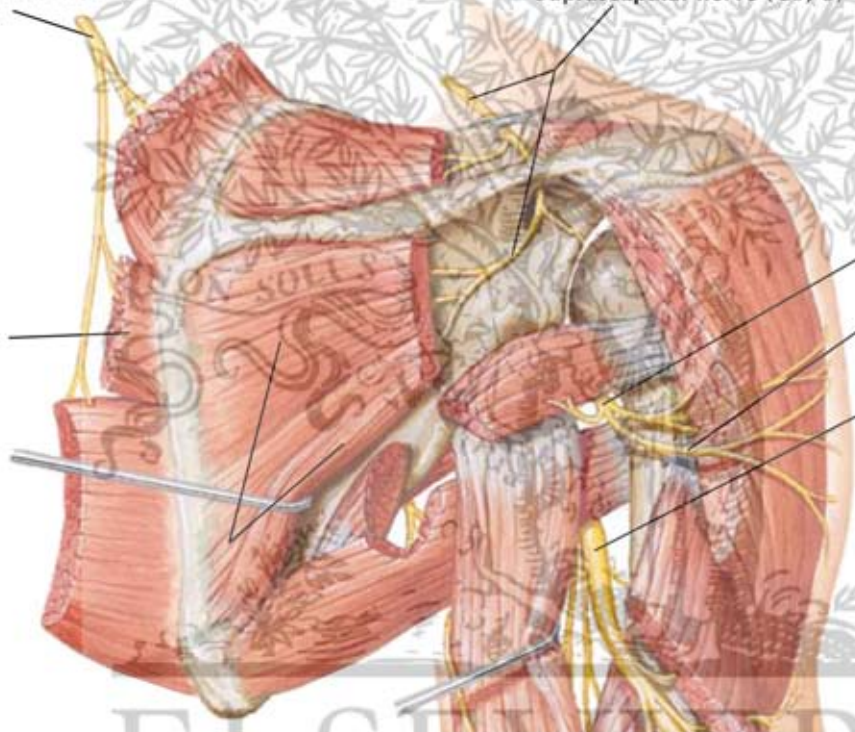
Axillary nerve (C5, 6)

Superior lateral cutaneous nerve of arm

Radial nerve (C5, 6, 7, 8, T1)

Inconstant contribution

Lower subscapular nerve (C5, 6)



F. Netter  
M.D.  
C. Machado  
M.D.