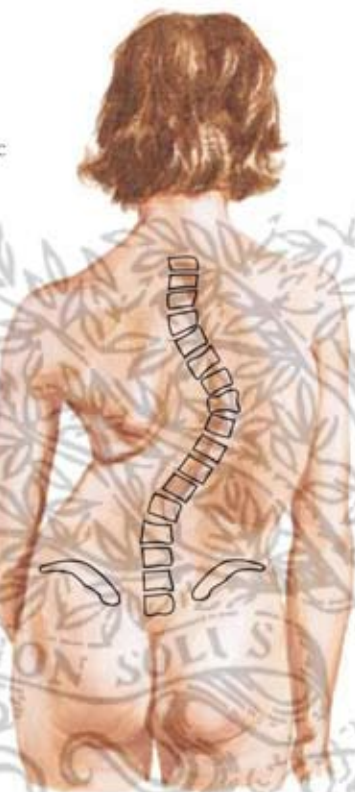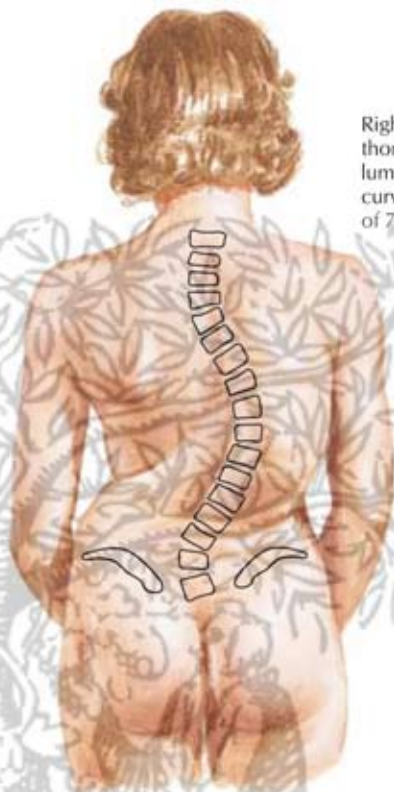


Scoliosis Curve Patterns

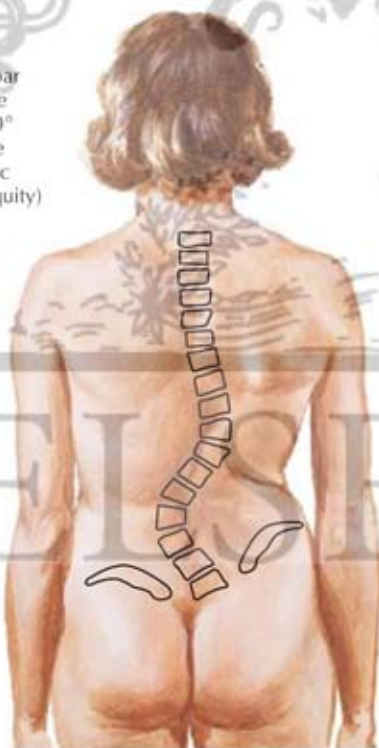
Right
thoracic
curve
of 70°



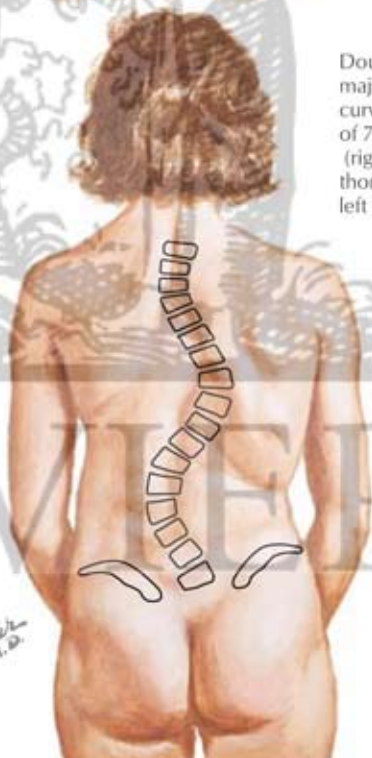
Right
thoraco-
lumbar
curve
of 70°



Left
lumbar
curve
of 70°
(note
pelvic
obliquity)



Double
major
curve
of 70°
(right
thoracic,
left lumbar)



F. Netter
M.D.