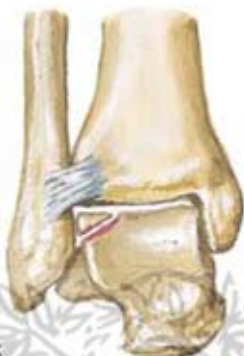

Fracture of Talus

Osteochondral fracture of talar dome

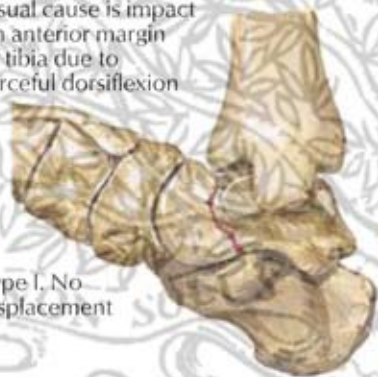
If fragment small, it may be removed; if large, it should be pinned in good apposition to restore congruity of articular surface



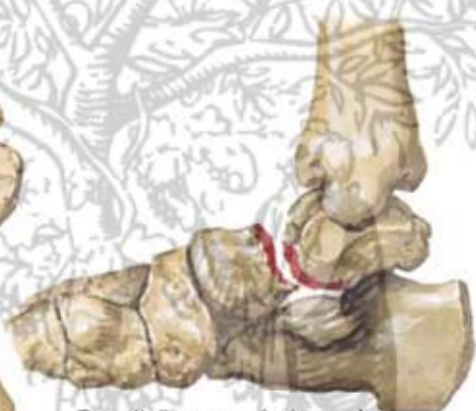Fracture of talar neck

Usual cause is impact on anterior margin of tibia due to forceful dorsiflexion

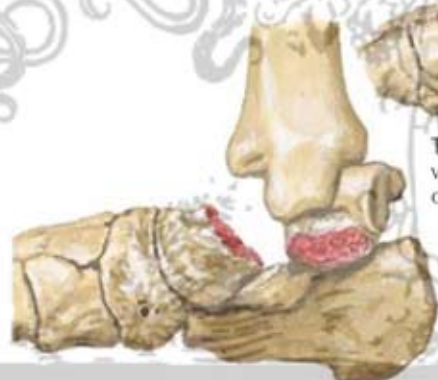Type I. No displacement



Type II. Fracture of talar neck with subluxation or dislocation of subtalar joint

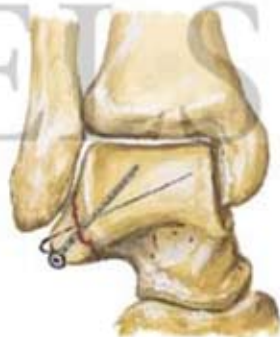

Type III. Fracture of talar neck with dislocation of subtalar and tibiotalar joints



Fracture of talar processes

Large fracture of lateral process fixed with Kirschner wire and lag screw



Fracture of posterior process. Irregularity of fracture line and comparison with other foot help differentiate it from congenital os trigonum

