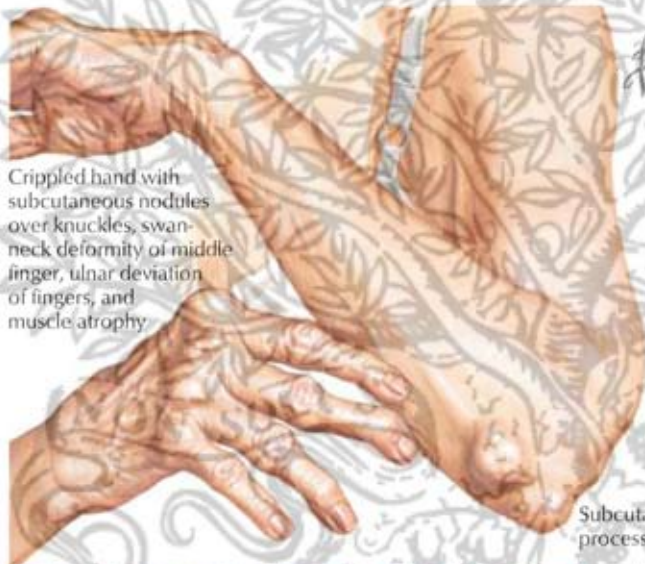
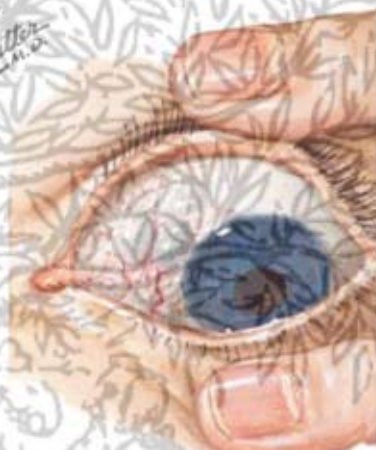

## Extraarticular Manifestations in Rheumatoid Arthritis

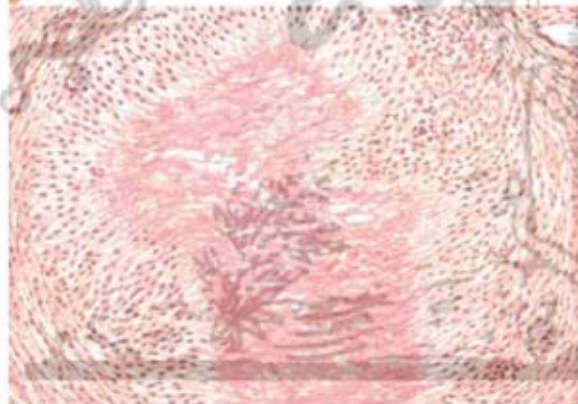


Crippled hand with subcutaneous nodules over knuckles, swan-neck deformity of middle finger, ulnar deviation of fingers, and muscle atrophy

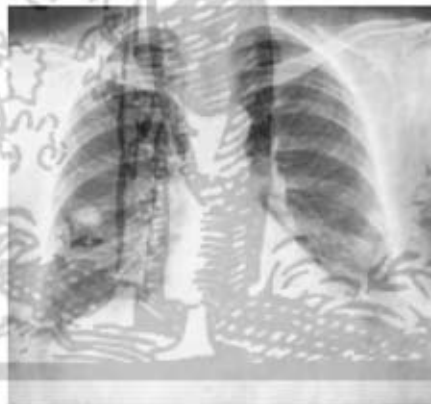


Nodular episcleritis with scleromalacia

Subcutaneous nodule just distal to olecranon process, and another in olecranon bursa



Section of rheumatoid nodule. Central area of fibrinoid necrosis surrounded by zone of palisading mesenchymal cells and peripheral fibrous tissue capsule containing chronic inflammatory cells.



Radiograph shows rheumatoid nodule in right lung. Lesion may be misdiagnosed as carcinoma until identified by biopsy or postsurgical pathologic analysis.