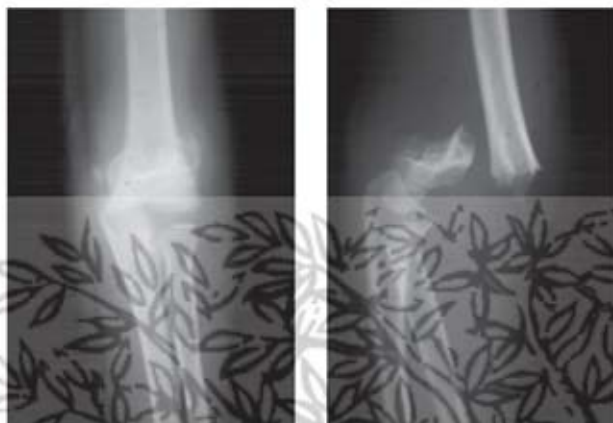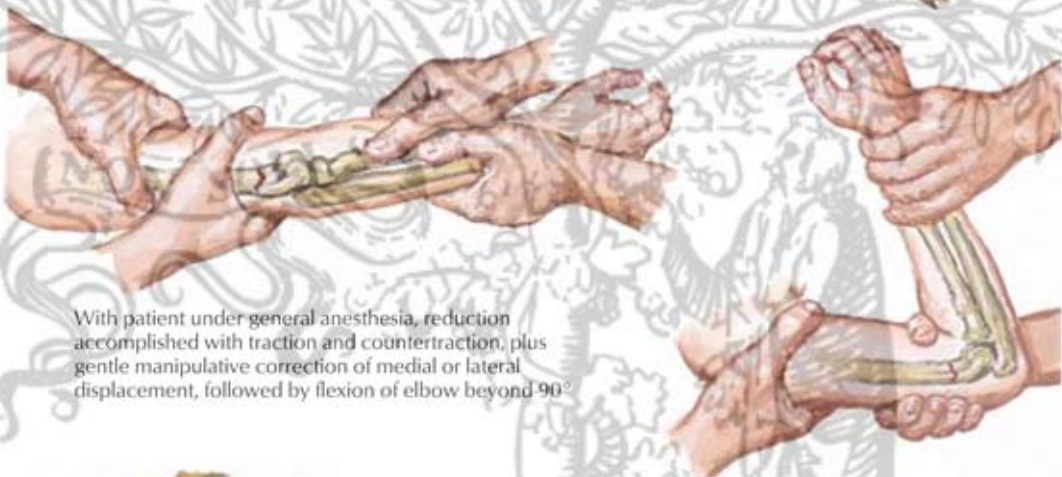

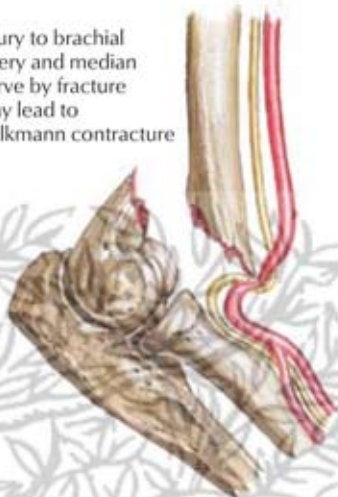
# Supracondylar Fracture of Humerus in Children

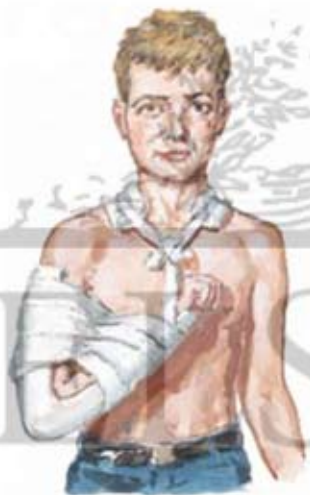

Anteroposterior (left) and lateral (right) radiographs. Displaced supracondylar fracture.

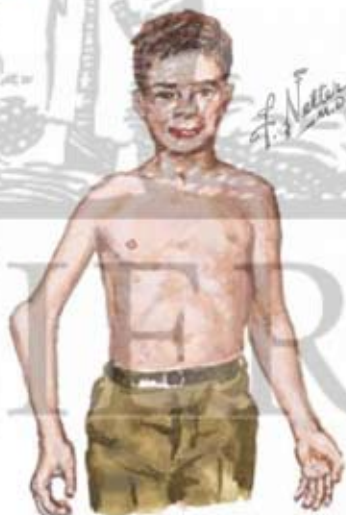
Injury to brachial artery and median nerve by fracture may lead to Volkmann contracture



With patient under general anesthesia, reduction accomplished with traction and countertraction, plus gentle manipulative correction of medial or lateral displacement, followed by flexion of elbow beyond 90°



Percutaneous pinning indicated if reduction difficult to maintain with closed method



Malunion producing cubitus varus with reversal of carrying angle is common complication

Posterior slab and figure-of-8 cast applied with elbow hyperflexed and worn for 3 weeks; antecubital fossa left exposed. Forearm pronated for medial displacement, supinated for lateral. Neck sling incorporated in plaster.