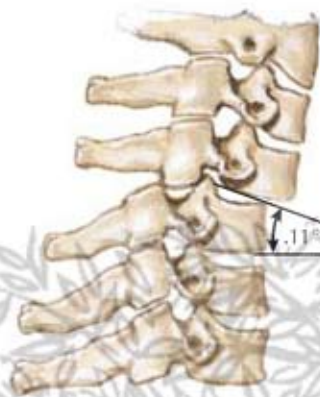
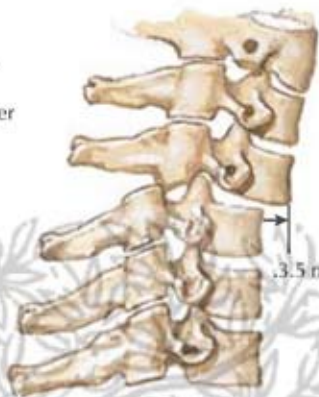
Subluxation and Ligamentous Instability of Cervical Spine

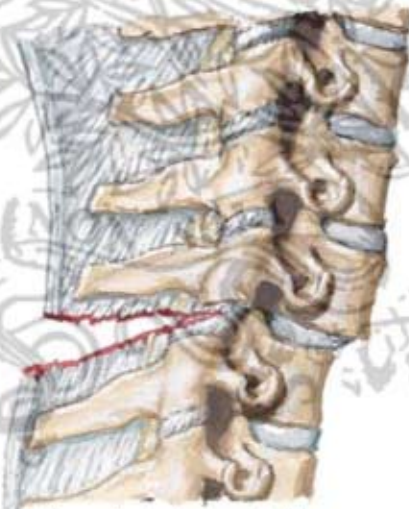


Subluxation with angulation greater than 11° and/or anterior displacement greater than 3.5 mm generally indicative of instability



Subluxation with angulation greater than 11°

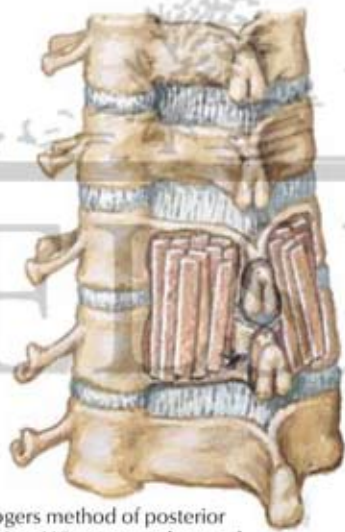Anterior displacement greater than 3.5 mm



Tear of interspinous and supraspinous ligaments characteristic of anterior dislocation of spine



Lateral radiograph shows severe kyphotic angulation in cervical dislocation



Rogers method of posterior fusion. Wire wrapped around spinous processes plus fusion of vertebrae.

F. Netter M.D.



Postoperative radiograph shows corrected alignment and fixation wire in place