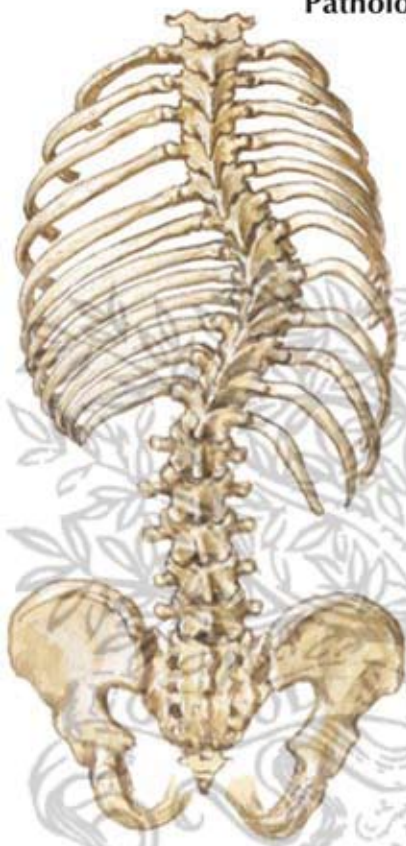
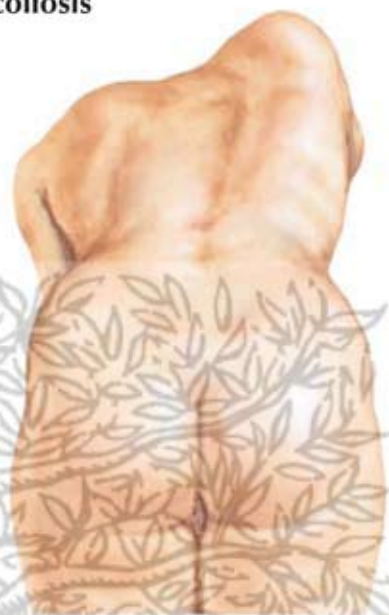
# Pathologic Anatomy of Scoliosis

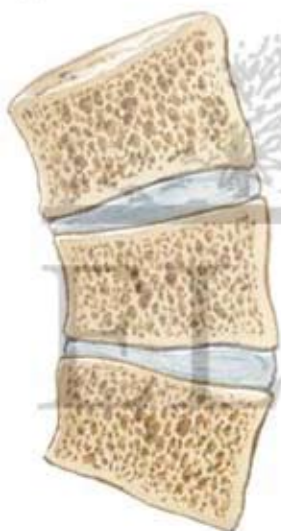

Ribs close together on concave side, widely separated on convex side. Vertebrae rotated with spinous processes and pedicles toward concavity.

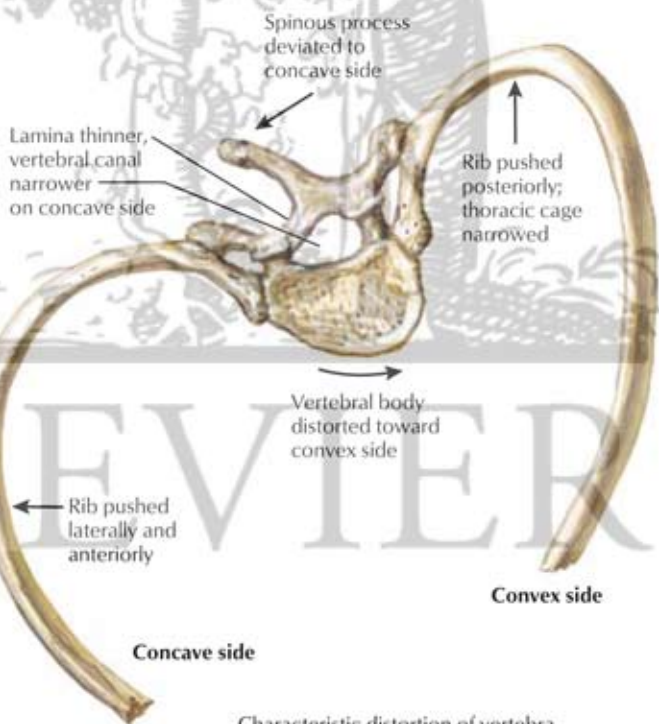


Posterior bulge of ribs on convex side forming characteristic rib hump in thoracic scoliosis

*F. Netter M.D.*



Section through scoliotic vertebrae. Decreased vertebral height and disc thickness on concave side.



Spinous process deviated to concave side

Lamina thinner, vertebral canal narrower on concave side

Rib pushed posteriorly; thoracic cage narrowed

Vertebral body distorted toward convex side

Rib pushed laterally and anteriorly

Concave side

Convex side

Characteristic distortion of vertebra and rib in thoracic scoliosis (inferior view)