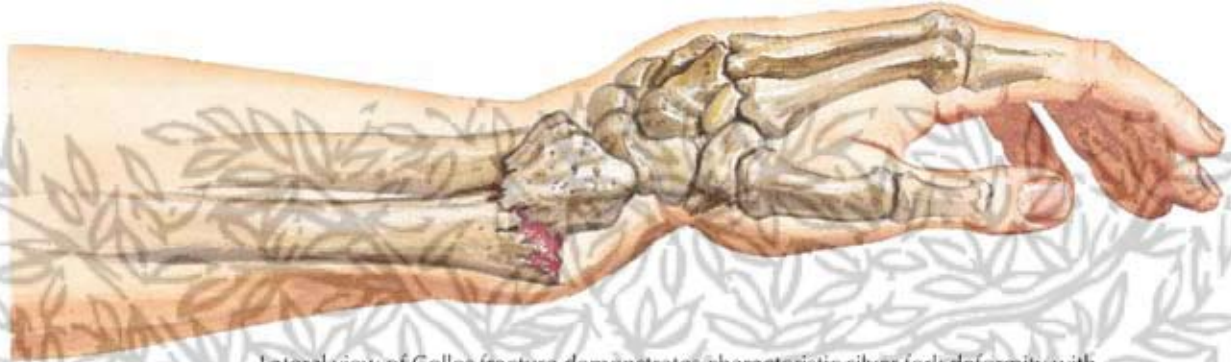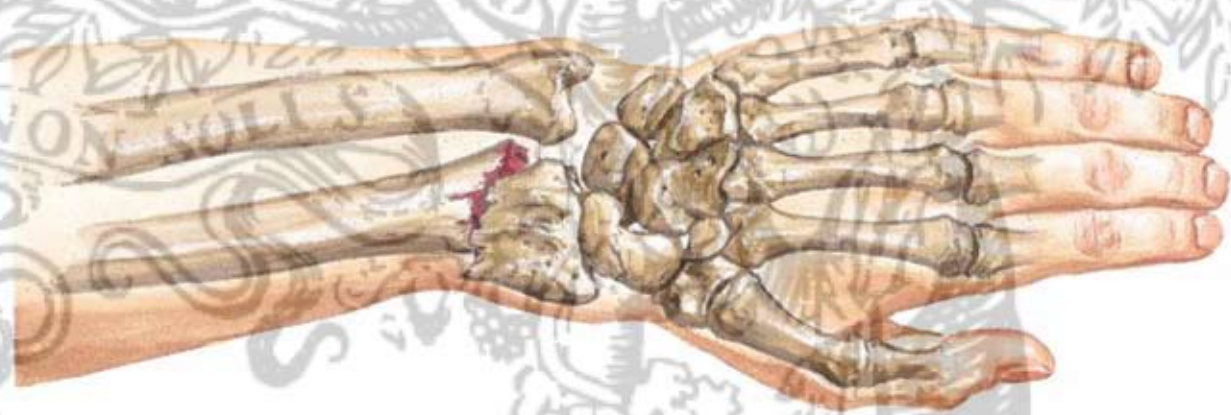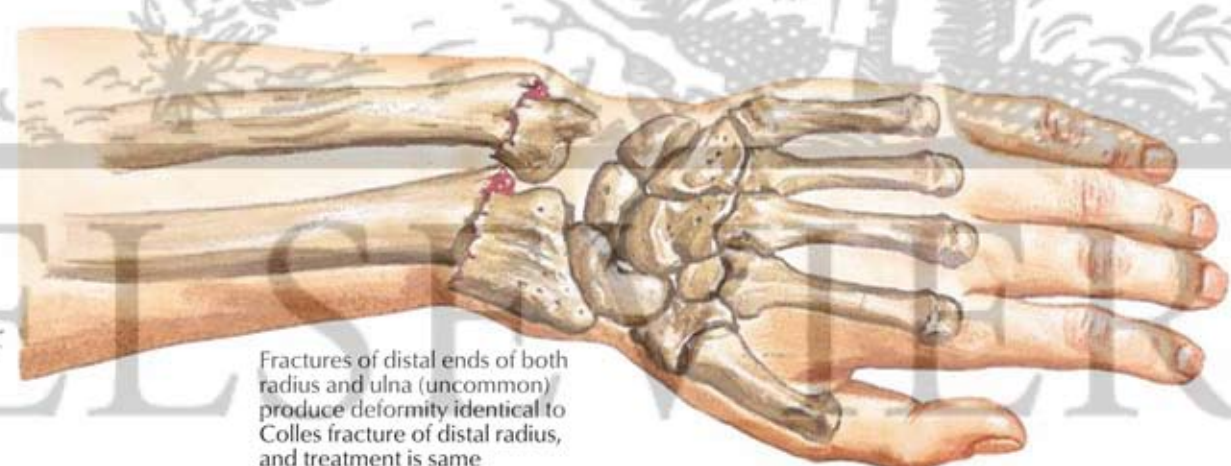




Lateral view of Colles fracture demonstrates characteristic silver fork deformity with dorsal and proximal displacement of distal fragment. Note dorsal instead of normal volar slope of articular surface of distal radius



Dorsal view shows radial deviation of hand with ulnar prominence of styloid process of ulna and decrease or reverse of normal radial slope of articular surface of distal radius



Fractures of distal ends of both radius and ulna (uncommon) produce deformity identical to Colles fracture of distal radius, and treatment is same

F. Netter M.D.