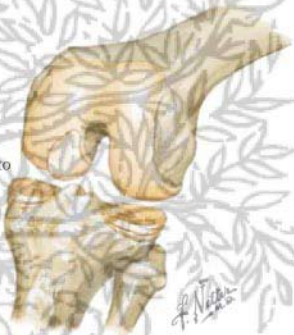




Pins introduced under arthroscopic control; drill attached to pins



Simple drilling of fragment to promote revascularization. Broken arrows indicate course of drill holes



Loose body in lateral gutter grasped with arthroscopic forceps and removed percutaneously



Pins drilled through fragment and medial femoral condyle, brought out through skin, pulled through until ends are just under surface of fragment. Pins left in place until healing occurs



Radiograph shows pins in place



Healing fragment on femoral condyle