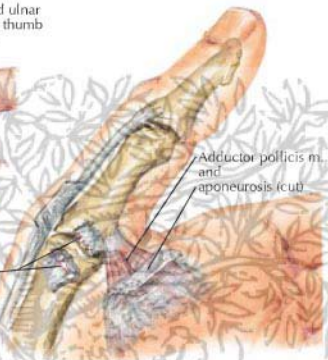
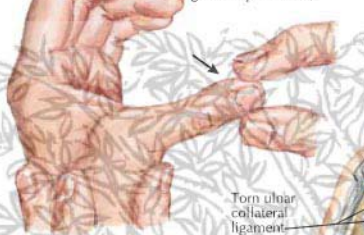


# Thumb Injury Other Than Fracture

Stress test for ruptured ulnar collateral ligament of thumb (gamekeeper thumb)

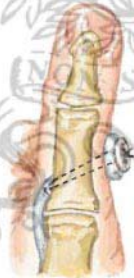

Torn ulnar collateral ligament

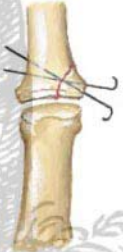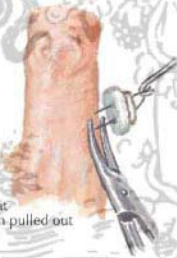Adductor pollicis m. and aponeurosis (cut)

Ruptured ulnar collateral ligament of metacarpophalangeal joint of thumb

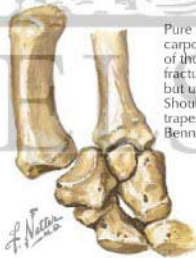
Avulsed collateral ligament may be reattached with pullout suture of Prolene tied over button with foam padding



Avulsion of bone fragment requires internal fixation to restore articular surface of metacarpophalangeal joint. Fine Kirschner wires used for large fragment, but pullout suture may be advantageous for small fragment



For removal, one limb of suture cut at skin level and suture pulled out



Pure dislocation of carpometacarpal joint of thumb without fracture is reducible but unstable. Should be pinned to trapezium, as for Bennett fracture



Position of hand on cassette for Robert view (true anteroposterior) radiograph. Robert view best visualizes carpometacarpal joint of thumb, and pathology may be missed if this view not taken