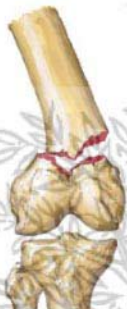
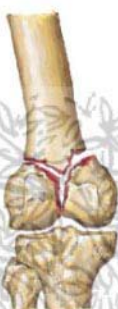
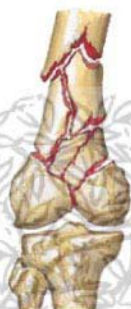Fractures of Distal Femur



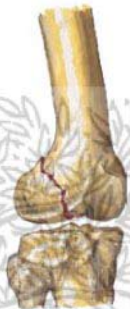Transverse supracondylar fracture



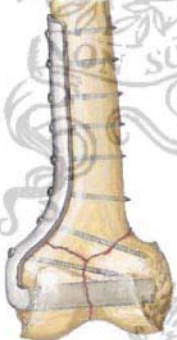
Intercondylar (T or Y) fracture



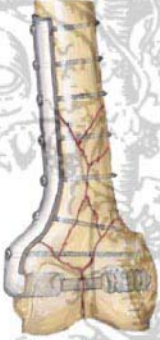Comminuted fracture extending into shaft



Fracture of single condyle (frontal or oblique plane)

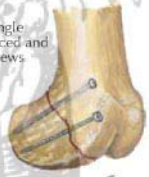

T Fracture fixed with blade plate inserted into condyles and secured with screws



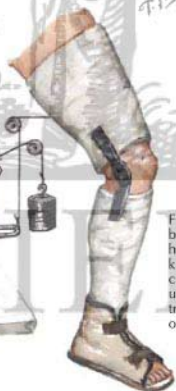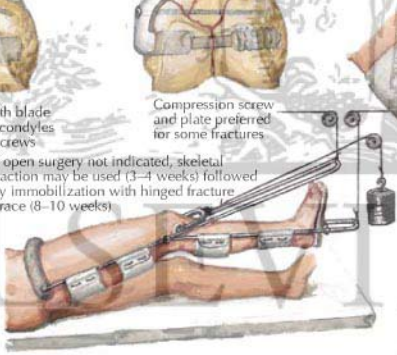
Compression screw and plate preferred for some fractures

Fracture of single condyle reduced and fixed with screws



*F. Netter M.D.*

If open surgery not indicated, skeletal traction may be used (3-4 weeks) followed by immobilization with hinged fracture brace (8-10 weeks)



Fracture brace hinged at knee and cast shoe used after traction or open repair