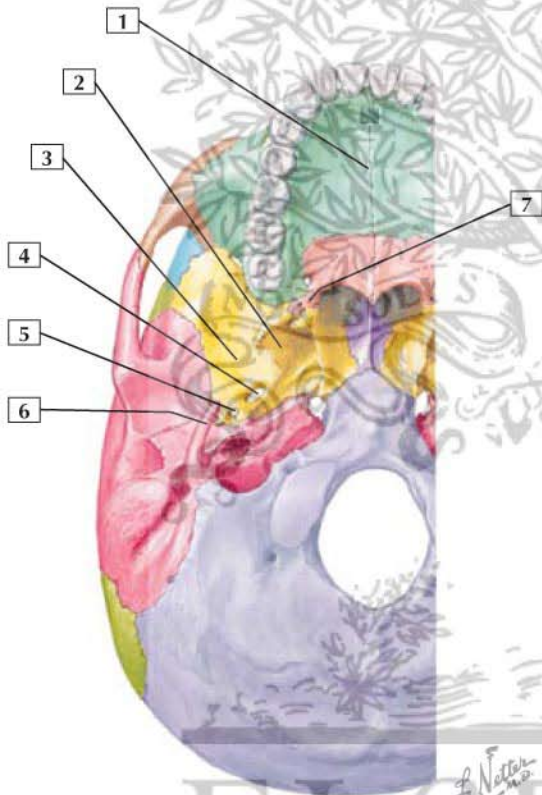


## Contents of the Infratemporal Fossa



1. Maxilla
2. Lateral pterygoid plate
3. Greater wing of the sphenoid
4. Foramen ovale
5. Foramen spinosum
6. Styloid process
7. Pyramidal process of the palatine

The infratemporal fossa is an irregularly shaped fossa inferior to that contains a series of muscles, vessels, and nerves.

Muscles include:

- Temporalis
- Lateral pterygoid
- Medial pterygoid

Arteries include the maxillary a. and its branches.

Veins include the pterygoid plexus of veins and tributaries.

Nerves include:

- Mandibular division of the trigeminal
- Posterior superior alveolar
- Chorda tympani branch of the facial
- Otic ganglion
- Lesser petrosal