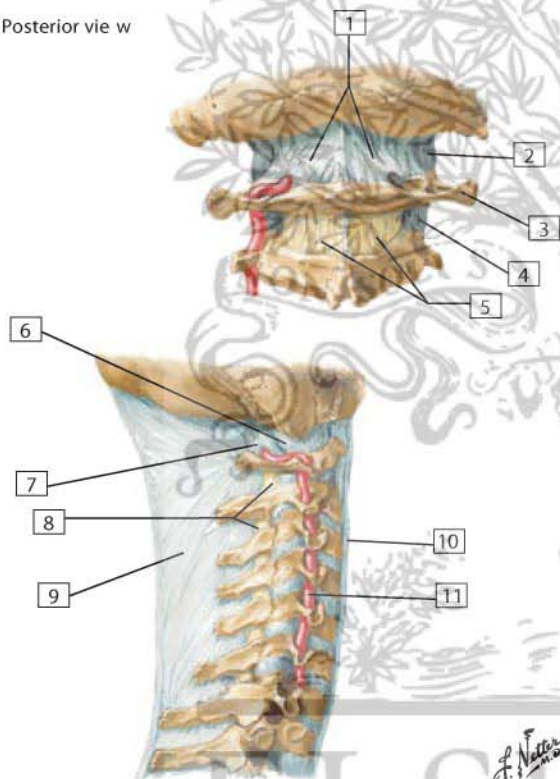


## External Craniocervical Ligaments

Posterior view w



1. Posterior atlanto-occipital membrane
2. Capsule of atlanto-occipital joint
3. Transverse process of atlas (C1)
4. Capsule of lateral atlantoaxial joint
5. Ligamenta flava
6. Capsule of atlanto-occipital joint
7. Posterior atlanto-occipital membrane
8. Ligamenta flava
9. Ligamentum nuchae
10. Anterior longitudinal ligament
11. Vertebral artery

**Comment:** The atlanto-occipital joint, on each side, is covered with an articular capsule and posteriorly reinforced by the posterior atlanto-occipital membrane.

The ligamentum nuchae is a strong median fibrous septum. It is an extension of the thickened supraspinous ligaments that arise from the spinous process of C7 and extend to the external occipital protuberance.

*F. Netter M.D.*

ELSEVIER